



Tidsskriftet  
DEN NORSKE LEGEFORENING

# Cerebral venous thrombosis – epidemiology, diagnosis and treatment

---

## KLINISK OVERSIKT

ESPEN SAXHAUG KRISTOFFERSEN

E-mail: [e.s.kristoffersen@medisin.uio.no](mailto:e.s.kristoffersen@medisin.uio.no)

Department of Neurology  
Akershus University Hospital and  
Department of General Practice  
Institute of Health and Society  
University of Oslo

He is the first author and had the original idea for the manuscript. He has contributed academically and scientifically, with revision of the manuscript, literature searches and data interpretation. Espen Saxhaug Kristoffersen (born 1980), PhD, specialty registrar in neurology, and associate professor.

The author has completed the ICMJE form and reports no conflicts of interest.

CHARLOTTE ELENA HARPER

Department of Neurology  
Akershus University Hospital

Charlotte Elena Harper (born 1983), specialty registrar in neurology.

She has contributed academically and scientifically, with revision of the manuscript, literature searches and data interpretation.

The author has completed the ICMJE form and reports no conflicts of interest.

KJERSTI GRØTTA VETVIK

Department of Neurology  
Akershus University Hospital

She has contributed academically and scientifically, with revision of the manuscript and data interpretation.

Kjersti Grøtta Vetvik (born 1978), PhD, specialist in neurology and senior consultant.

The author has completed the ICMJE form and reports no conflicts of interest.

KASHIF WAQAR FAIZ

Department of Neurology  
Akershus University Hospital  
and

Health Services Research Centre  
Akershus University Hospital

He had the original idea for the manuscript and has contributed academically and scientifically, with revision of the manuscript, literature searches and data interpretation.

Kashif Waqar Faiz (born 1978), PhD, MSc in healthcare administration, specialist in neurology, head of section/senior consultant and researcher.

The author has completed the ICMJE form and reports no conflicts of interest.

Cerebral venous thrombosis is a rare condition, but nevertheless among the most common causes of stroke in persons under 45 years of age. The condition can pose challenges for clinicians.

The diagnosis and management of cerebral venous thrombosis have been well described in the international scientific literature. However, new studies and updated guidelines have been published in recent years (1–3). Based on this, we have written a clinical review based on the existing literature, the updated guidelines and our own clinical experience.

## Incidence

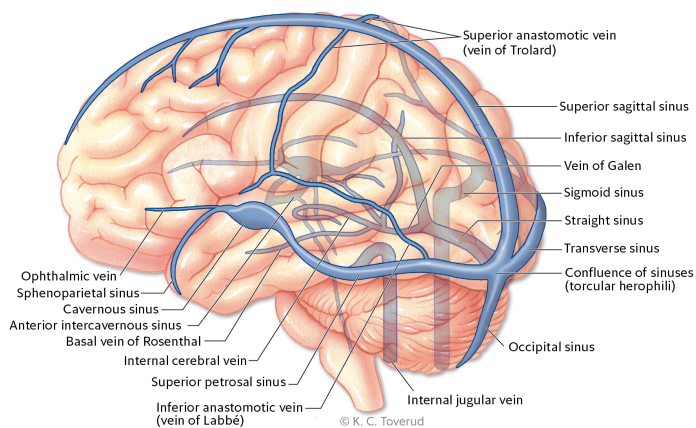
The incidence of cerebral venous thrombosis has long been estimated to be around 0.3–0.5/100 000/year, but recent studies have reported a higher incidence of around 1–1.5/100 000/year (3, 4). Whether this change reflects a genuine increase in incidence or simply greater awareness of the condition, as well as better and more accessible diagnostic imaging, is uncertain. Cerebral venous thrombosis accounts for less than 1% of all cases of stroke worldwide.

The incidence varies in different parts of the world, being higher in Asia, the Middle East and Africa (3, 4). This is probably due to a higher occurrence of known risk factors, such as multiple pregnancies, untreated inflammatory conditions, as well as infections and injuries of the central nervous system. Known risk factors and causes of cerebral venous thrombosis are venous thromboembolism, pregnancy, oestrogen therapy/oral contraceptives, thrombophilia (especially antithrombin deficiency, protein C and S deficiency and factor V Leiden mutation), hypercoagulability as part of inflammatory disease, head trauma, local infections and underlying cancer (3, 5, 6).

The condition is three times more common in women of reproductive age than in men, probably owing to pregnancy and the use of oral contraceptives (7).

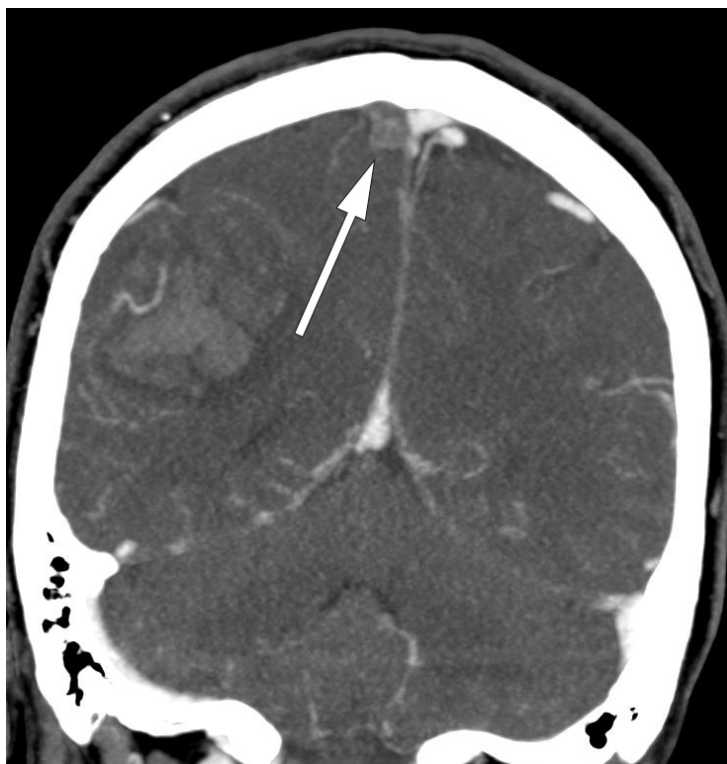## Pathophysiology

The cerebral venous system is made up of both a superficial and a deep venous system (Fig. 1)(3, 8).



**Figure 1** Overview of cerebral venous system

An obstruction resulting from venous thrombosis in dural/cortical veins or a venous sinus (Fig. 2) will give rise to increased venous pressure and reduced capillary perfusion. Initially, the extensive cerebral collateral network will compensate for this, but when the capacity of this network is also exceeded, the result will be venous stasis, increased intramural pressure, and damage to veins and the blood-brain barrier, which will in turn give rise to vasogenic oedema and haemorrhagic infarcts. In addition, the reduction in cerebral perfusion will lead to cytotoxic oedema and a further increase in intracranial pressure. Obstruction of cerebral sinuses may also result in reduced absorption of cerebrospinal fluid, increasing intracranial pressure still further.



**Figure 2** CT venography showing a filling defect in the right superior sagittal sinus, consistent with a partial occlusive thrombus

## Clinical presentation

Symptom onset may be acute, subacute or chronic, and the presentation is highly variable (3, 5, 8). Delayed diagnosis is not uncommon (9). Headache is reported as an initial symptom in 60–90 % of patients, but in contrast to subarachnoid haemorrhage, for example, the headache usually begins in a subacute form that develops over several days, although acute headache is also described.

The headache may be pulsating or pressing/tightening, and either unilateral or bilateral. Focal or generalised seizures occur in 30–40 % of patients, which is a markedly higher incidence than in cases of arterial cerebral infarction (2–9 %) or intracerebral haemorrhage (8–14 %) (3, 10). Papilloedema owing to increased intracranial pressure is reported in 30–60 % of patients (3). Focal neurological deficits are described in 30–50 %, with the most common being monoparesis or hemiparesis. Approximately 10 % of patients are comatose at the time of diagnosis (3, 5, 6).

Differing anatomical positions of the thrombus give rise to different clinical presentations (3). Patients with thrombosis in a major venous sinus usually experience headache, nausea, papilloedema, decreased visual acuity and varying degrees of altered consciousness as a result of intracranial hypertension. Seizures and other focal neurological deficits often occur in cases where there is thrombosis of the more superficial veins, or with cortical/subcortical lesions. Thrombosis of the deeper veins can give rise to oedema in the area around the basal ganglia and thalamus with encephalopathy, altered mental status, lateralised symptoms, movement disorders and possibly coma. Thrombosis of the cavernous sinuses gives rise primarily to retrobulbar pain and ophthalmoplegia.

## Examination and diagnosis

New-onset non-episodic headache associated with neurological deficits should always be investigated. Cerebral venous thrombosis should be suspected in cases of new-onset progressive headache, and especially where there are known predisposing factors such as thrombophilia, pregnancy, childbirth or the use of hormonal contraceptives. No specific laboratory tests confirm the diagnosis (1, 2). An elevated D-dimer level may support the

diagnosis, but a normal D-dimer level is not sufficient to rule out the condition (11). The use of D-dimer has 93.9 % sensitivity and 89.7 % specificity in persons with suspected cerebral venous thrombosis, although these figures are lower in cases of isolated headache or symptoms lasting more than one week (11).

Upon strong clinical suspicion of cerebral venous thrombosis, or if head CT reveals lobar intraparenchymal haemorrhage or infarct-related lesions that do not follow the usual arterial tree, further diagnostic imaging must be performed (1–3). Head CT without contrast has low sensitivity (40–70 %), and the addition of intravenous contrast may reveal a hyperdense filling defect in the venous sinuses (including the ‘empty delta sign’ in the superior sagittal sinus). However, in more than 30 % of cases neither direct nor indirect signs of cerebral venous thrombosis are seen on CT scans (3, 12).

Both CT- and MR venography can confirm a diagnosis of cerebral venous thrombosis, but MR venography is probably more sensitive in the acute phase (3, 13, 14). MR venography also provides superior visualisation of the brain parenchyma, venous infarcts and haemorrhages, and is thus the preferred imaging modality (1). Venous infarcts occur in approximately 60 % of patients and differ from arterial infarcts in that they cross arterial boundaries (3).

Almost two thirds of venous infarcts have a haemorrhagic component with significantly greater oedema than in cases of arterial infarction. The utility of transcranial Doppler in cerebral venous thrombosis has not been systematically examined, and conventional invasive imaging is generally unnecessary.

Testing of all patients for thrombophilia has been recommended previously, but this no longer features in European guidelines owing to weak supporting evidence (1). In the event of a known family history, young age, or the absence of other known precipitating factors, we recommend testing for congenital thrombophilia (activated protein C resistance; factor V Leiden mutation; deficiency of antithrombin III, protein C and protein S, or mutation in the prothrombin gene) and for systemic inflammatory conditions associated with hypercoagulability (ANA, ANCA and lupus anticoagulant). The tests for antithrombin III, protein C and protein S are non-specific in the acute phase and should be postponed until at least four weeks after completion of anticoagulant therapy.

Lumbar puncture and testing of cerebrospinal fluid are not indicated in the workup for cerebral venous thrombosis. Routine screening of patients for underlying cancer is not recommended either (1).

## Treatment

Guidelines for the treatment of cerebral venous thrombosis have been published by the European Stroke Organisation (ESO)/European Academy of Neurology (EAN) and the American Heart Association/American Stroke Association (1, 2), but there are few data available on treatment in Norway.

We fully concur with the international guidelines that patients with cerebral venous thrombosis should be treated in a stroke unit. Treatment must focus on anticoagulation therapy and symptom management with a view to preventing complications and death.

Although almost two-thirds of patients have venous haemorrhagic infarcts in the acute phase, anticoagulation with low molecular weight heparin is the recommended treatment for all patients, including pregnant women (dalteparin 100 IU/kg x 2 or enoxaparin 1 mg/kg x 2) (1). This recommendation is based on two small randomised controlled studies that showed a non-significant clinical difference between low molecular weight heparin and placebo, but equally importantly showed that heparin did not increase the risk of haemorrhage (15).

After initial anticoagulation therapy with low molecular weight heparin, a switch to a vitamin K antagonist (warfarin) is recommended over the course of a few days. A lack of

randomised studies means that there is uncertainty regarding the optimal duration of warfarin treatment. An international multicentre study comparing 3–6 months of treatment versus 12 months is ongoing. Meanwhile, 3–6 months is recommended if a transient cause of cerebral venous thrombosis is identified (for example, pregnancy), and 6–12 months if there is no known precipitating factor (1). The aim of treatment is to achieve an INR value of 2.5 (1).

Lifelong anticoagulation treatment must be considered carefully in the event of recurrent cerebral venous thrombosis, known thrombophilia or multiple prothrombotic conditions. As current knowledge is lacking, we suggest following specific recommendations for the prevention of recurrent venous thromboembolic events in those conditions (1).

There are as yet no completed studies with the new direct-acting oral anticoagulants (DOACs), and only case reports are described in the literature (1). At least three DOAC studies are currently ongoing, with the results expected in 2018–20 (3).

There is no evidence to support systemic intravenous thrombolysis in cases of cerebral venous thrombosis (16). The available evidence is too weak to support the routine use of thrombectomy and other forms of endovascular treatment, such as stenting, but these may be used in individual cases where severe clinical deterioration occurs despite full medical treatment (1, 17).

Independently of treatment strategy, studies show partial or complete recanalisation in 50–90 % of patients (3). Recanalisation occurs gradually over time, and improvements may be seen on diagnostic imaging as late as 11 months after disease onset. The clinical significance of this is uncertain, as studies comparing degree of recanalisation with prognosis have yielded conflicting results, and have used different grading scales and classifications (3).

Increased intracranial pressure is common in the acute phase of cerebral venous thrombosis. Headache resulting from increased intracranial pressure may be treated with analgesics, whereas steroids and acetazolamide are no longer routinely recommended for intracranial pressure reduction owing to weak supporting evidence (1). Surgical decompression in the event of increased intracranial pressure and impending transtentorial cerebral herniation may be lifesaving in the acute phase (1, 18). About 15 % of patients develop obstructive hydrocephalus as a result of cerebral oedema, but ventriculoperitoneal shunting is not recommended as routine practice (1).

Patients who experience seizures should be treated with anti-epileptic drugs and those who experience seizures in the acute phase and/or parenchymal haemorrhage are at increased risk of further seizures (10). The optimal duration of treatment with anti-epileptic drugs is unknown. Previous guidelines advised treatment for one year, but this recommendation has been removed in the absence of definitive evidence to support it (3).

Visual field deficits in cases of cerebral venous thrombosis usually resolve and <10 % have persistently impaired vision (3).

There is no consensus regarding the follow-up of patients after cerebral venous thrombosis. In our experience, the need for and usefulness of follow-up appointments varies from patient to patient, but we believe there should be a clinical follow-up after three months. Further appointments must be tailored to the needs of the individual, but it is reasonable to continue with follow-up for as long as the patient is taking anticoagulants and/or anti-epileptic drugs.

The usefulness of MRI scans in the follow-up is unclear, and such scans rarely have consequences for treatment. However, we feel it is reasonable to consider MR venography after six months, primarily to obtain new MRI data following the acute episode, which can then serve as a new baseline should the patient experience new symptoms of cerebral venous thrombosis.

## Disease course and prognosis

The clinical course of cerebral venous thrombosis is, in common with the clinical presentation, unpredictable and highly variable (3, 6, 19). About one in four patients experiences a transient deterioration in the acute phase. Owing to the distinct pathophysiological mechanisms underlying arterial and venous infarcts, their respective prognoses are very different; prognosis is consistently significantly better in cases of cerebral venous thrombosis than in cases of ischaemic infarction (3). About one in ten patients have persistent neurological deficits, such as speech impairment and sensory and motor symptoms at one-year follow-up. However, about half of patients experience residual chronic symptoms such as persistent headache, tiredness, depression or subtle neuropsychological problems. International studies have shown that 20–40 % of patients either do not return to work or work fewer hours than they did prior to the onset of their illness (20, 21).

Risk factors for poor outcomes are increased age, male sex, mental disorders, larger haemorrhagic infarct, intracranial haemorrhage and coma as part of the disease course, infection of the central nervous system and underlying cancer (3, 5, 6).

Mortality in the acute phase is estimated at 4–5 % (3, 22). The most common cause of death in the acute phase is transtentorial herniation (30–50 %), while other common causes of early death are status epilepticus and medical complications, such as sepsis and pulmonary embolism (3). Total mortality is approximately 10 %, with about half of these deaths attributable to an underlying condition, most often cancer.

The risk of a second cerebral venous thrombosis is highest during the first year after the original episode, but is nevertheless estimated to be less than 5 % (3, 6). Women with a history of cerebral venous thrombosis are advised to avoid oestrogen-containing contraceptives (1). However, the risk of a new pregnancy-related cerebral venous thrombosis in women who have experienced cerebral venous thrombosis in a previous pregnancy is considered low. Further pregnancies are not discouraged, but low molecular weight heparin should be used as prophylaxis throughout pregnancy and birth.

## Conclusion

Cerebral venous thrombosis is a rare but feared condition that can easily be overlooked in the acute phase owing to a highly variable clinical picture. The diagnosis should be suspected in cases of subacute headache accompanied by other focal neurological deficits, seizures or altered consciousness.

---

### REFERENCES:

1. Ferro JM, Boussier MG, Canhão P et al. European Stroke Organization guideline for the diagnosis and treatment of cerebral venous thrombosis – endorsed by the European Academy of Neurology. *Eur J Neurol* 2017; 24: 1203 - 13. [PubMed][CrossRef]
2. Saposnik G, Barinagarrementeria F, Brown RD et al. Diagnosis and management of cerebral venous thrombosis: a statement for healthcare professionals from the American Heart Association/American Stroke Association. *Stroke* 2011; 42: 1158 - 92. [PubMed][CrossRef]
3. Silvis SM, de Sousa DA, Ferro JM et al. Cerebral venous thrombosis. *Nat Rev Neurol* 2017; 13: 555 - 65. [PubMed][CrossRef]
4. Devasagayam S, Wyatt B, Leyden J et al. Cerebral venous sinus thrombosis incidence is higher than previously thought: a retrospective population-based study. *Stroke* 2016; 47: 2180 - 2. [PubMed][CrossRef]
5. Duman T, Uluduz D, Mido I et al. A Multicenter study of 1144 patients with cerebral venous thrombosis: The VENOST Study. *J Stroke Cerebrovasc Dis* 2017; 26: 1848 - 57. [PubMed][CrossRef]
6. Ferro JM, Canhão P, Stam J et al. Prognosis of cerebral vein and dural sinus thrombosis: results of the

- International Study on Cerebral Vein and Dural Sinus Thrombosis (ISCVT). *Stroke* 2004; 35: 664 - 70. [PubMed][CrossRef]
7. Coutinho JM, Ferro JM, Canhão P et al. Cerebral venous and sinus thrombosis in women. *Stroke* 2009; 40: 2356 - 61. [PubMed][CrossRef]
  8. Johnsen HJ, Vorhaug A, Kvistad KA. Cerebral venous thrombosis–diagnosis and treatment. *Tidsskr Nor Lægeforen* 2007; 127: 1069 - 73. [PubMed]
  9. Ferro JM, Canhão P, Stam J et al. Delay in the diagnosis of cerebral vein and dural sinus thrombosis: influence on outcome. *Stroke* 2009; 40: 3133 - 8. [PubMed][CrossRef]
  10. Ferro JM, Canhão P, Boussier MG et al. Early seizures in cerebral vein and dural sinus thrombosis: risk factors and role of antiepileptics. *Stroke* 2008; 39: 1152 - 8. [PubMed][CrossRef]
  11. Dentali F, Squizzato A, Marchesi C et al. D-dimer testing in the diagnosis of cerebral vein thrombosis: a systematic review and a meta-analysis of the literature. *J Thromb Haemost* 2012; 10: 582 - 9. [PubMed][CrossRef]
  12. Rizzo L, Crasto SG, Rudà R et al. Cerebral venous thrombosis: role of CT, MRI and MRA in the emergency setting. *Radiol Med (Torino)* 2010; 115: 313 - 25. [PubMed][CrossRef]
  13. Lafitte F, Boukobza M, Guichard JP et al. MRI and MRA for diagnosis and follow-up of cerebral venous thrombosis (CVT). *Clin Radiol* 1997; 52: 672 - 9. [PubMed][CrossRef]
  14. Ozsvath RR, Casey SO, Lustrin ES et al. Cerebral venography: comparison of CT and MR projection venography. *AJR Am J Roentgenol* 1997; 169: 1699 - 707. [PubMed][CrossRef]
  15. Coutinho J, de Bruijn SF, Deveber G et al. Anticoagulation for cerebral venous sinus thrombosis. *Cochrane Database Syst Rev* 2011; 8: CD002005. [PubMed]
  16. Viegas LD, Stolz E, Canhão P et al. Systemic thrombolysis for cerebral venous and dural sinus thrombosis: a systematic review. *Cerebrovasc Dis* 2014; 37: 43 - 50. [PubMed][CrossRef]
  17. Ilyas A, Chen CJ, Raper DM et al. Endovascular mechanical thrombectomy for cerebral venous sinus thrombosis: a systematic review. *J Neurointerv Surg* 2017; 9: 1086 - 92. [PubMed][CrossRef]
  18. Aaron S, Alexander M, Moorthy RK et al. Decompressive craniectomy in cerebral venous thrombosis: a single centre experience. *J Neurol Neurosurg Psychiatry* 2013; 84: 995 - 1000. [PubMed][CrossRef]
  19. Dentali F, Gianni M, Crowther MA et al. Natural history of cerebral vein thrombosis: a systematic review. *Blood* 2006; 108: 1129 - 34. [PubMed][CrossRef]
  20. Hiltunen S, Putaala J, Haapaniemi E et al. Long-term outcome after cerebral venous thrombosis: analysis of functional and vocational outcome, residual symptoms, and adverse events in 161 patients. *J Neurol* 2016; 263: 477 - 84. [PubMed][CrossRef]
  21. Bugnicourt JM, Guegan-Massardier E, Roussel M et al. Cognitive impairment after cerebral venous thrombosis: a two-center study. *J Neurol* 2013; 260: 1324 - 31. [PubMed][CrossRef]
  22. Coutinho JM, Zuurbier SM, Stam J. Declining mortality in cerebral venous thrombosis: a systematic review. *Stroke* 2014; 45: 1338 - 41. [PubMed][CrossRef]

---

Published: 21 August 2018. *Tidsskr Nor Legeforen*. DOI: 10.4045/tidsskr.17.1047

Received 28.11.2017, first revision submitted 23.3.2018, accepted 16.5.2018.

© The Journal of the Norwegian Medical Association 2020. Downloaded from tidsskriftet.no