



# A three year-old boy with back pain, fever and cola-coloured urine

---

NOE Å LÆRE AV

SILJE AGNETHE STOKKE KVISTAD

E-mail: [sgns@helse-bergen.no](mailto:sgns@helse-bergen.no)

Department of Immunology and Transfusion Medicine

Haukeland University Hospital

and

University of Bergen

Silje Agnethe Stokke Kvistad is a specialty registrar in immunology and transfusion medicine and a PhD research fellow.

The author has completed the ICMJE form and reports no conflicts of interest.

MARIA WINTHER GUNNES

Division of Paediatric and Adolescent Medicine

Haukeland University Hospital

Maria Winther Gunnes PhD is a paediatrician and senior consultant.

The author has completed the ICMJE form and reports no conflicts of interest.

KRISTIN GJERDE HAGEN

Department of Immunology and Transfusion Medicine

Haukeland University Hospital

Kristin Gjerde Hagen is a specialist in immunology and transfusion medicine and a senior consultant.

The author has completed the ICMJE form and reports no conflicts of interest.

SIGBJØRN BERENTSEN

Section for Research and Innovation

Haugesund Hospital

Sigbjørn Berentsen Dr. med. is a specialist in internal medicine and a former head of section and senior lecturer. He has done research on autoimmune haemolytic anaemia with the emphasis on cold agglutinin disease.

The author has completed the ICMJE form and reports no conflicts of interest.

Maria Winther Gunnes and Kristin Gjerde Hagen have contributed equally to this article.

---

Anaemia is a common problem in children. Sometimes the cause is easy to diagnose, for example iron deficiency or infection. At other times, rare conditions which challenge the clinician are encountered, as illustrated by our case report.

A three year-old boy was assessed at A&E because of abdominal and back pain. A week previously he had had an eye and ear infection and had been treated effectively with penicillin orally and with fucidin eye drops. He now had a fever, back pain and discoloured urine. Urine dipsticks showed haemoglobin 3+, nitrite 1+, protein 1+. C-reactive protein

(CRP) was 119 mg/l (< 5 mg/l).

The A&E doctor suspected a urinary tract infection, but wanted to exclude glomerulonephritis. The patient was referred to the Paediatric Department.

On admission, his previous medical history was reviewed. As a one year-old he had been hospitalised with sepsis with no definite focus of infection. The same year he had received a diagnosis of asthma, and since then had had frequent respiratory tract infections. He used inhalation steroids regularly (fluticasone 50 µg x 2) and an adrenergic drug (salbutamol 0.1 mg x 4). In recent months he had had intermittent pain in both knees and had been referred to Paediatric Outpatients.

Blood tests showed haemoglobin 11.4 g/dl (10.6–13.8 g/dl), leukocytes  $10.2 \cdot 10^9/l$  ( $5.5\text{--}12.5 \cdot 10^9/l$ ), thrombocytes  $226 \cdot 10^9/l$  ( $228\text{--}435 \cdot 10^9/l$ ) and CRP 142 mg/l. Urine dipsticks showed haemoglobin 1+, leukocytes 1+ and protein 1+. The duty paediatrician assessed it as probably being pyelonephritis and the child was discharged with a course of mecillinam by mouth 10 mg/kg x 3.

Two days later the boy arrived at Outpatients for a scheduled examination to assess his knee pain. He was now icteric and in considerably reduced general condition and was hospitalised. He was afebrile and with stable circulation, but had slight tachycardia with a pulse of 135/minute (70–110/min) and blood pressure 90/50 mm Hg (80–105/40–60). Blood tests showed haemoglobin 7.0 g/dl, CRP 83 mg/l and leukocytes  $15.9 \cdot 10^9/l$ . Intravenous therapy with ampicillin and gentamicin was started. Several diagnoses were now considered, including glomerulonephritis, haemolytic uraemic syndrome and sepsis.

A positive test for “blood” on urine dipsticks usually indicates erythrocytes in the urine (haematuria), but may alternatively be due to free haemoglobin (haemoglobinuria), which was probably the case here. The two can usually be distinguished easily by means of urine microscopy, which unfortunately was not carried out. Children with acute glomerulonephritis usually present with haematuria and symptoms of excess fluid, and some may have renal failure. The most common aetiology in children is a streptococcus infection of the throat or upper airways. Haemolytic uraemic syndrome mainly affects children aged 1–5 years, and is characterised by the triad of haemolytic anaemia, thrombocytopenia and acute renal failure. Patients often have haematuria (1).

Ultrasound of the abdomen showed a moderately enlarged spleen. Ultrasound of the knees was normal. Bilirubin was 75 µmol/l (< 19 µmol/l), lactate dehydrogenase 1700 U/l (< 400 U/l), haptoglobin < 0.10 g/l (0.4–1.9 g/l), thrombocytes  $248 \cdot 10^9/l$  and reticulocytes  $95 \cdot 10^9/l$  ( $36\text{--}60 \cdot 10^9/l$ ). Blood smears showed no schistocytes, as expected with haemolytic uraemic syndrome, but granulocytosis and monocytosis consistent with infection or inflammation. A polyspecific (“simple”) direct antiglobulin test was positive. A monospecific (“extended”) direct antiglobulin test was positive for C3c and C3d, consistent with autoimmune haemolytic anaemia with complement activation.

A high bilirubin level is seen with liver pathology and haemolysis. Differential diagnosis can be attempted by specifically measuring unconjugated (indirectly reacting) and conjugated (directly reacting) bilirubin. In practice the objective is usually attained by comparing total bilirubin levels with other liver tests (first and foremost transaminases) and haemolysis parameters (haptoglobin, lactate dehydrogenase and if relevant the absolute reticulocyte count). In this case, the high bilirubin level was quite clearly due to haemolysis.

In cases of autoimmune haemolytic anaemia there are autoantibodies against erythrocytes, and the disease group is divided into warm antibody type, cold antibody type and mixed type. The condition is rare in children (2). When an anaemia is found to be haemolytic, a direct antiglobulin test (DAT, formerly called direct Coombs’ test) is carried out to detect autoimmune pathogenesis with immunoglobulin and/or complement protein on the erythrocyte surface. Monospecific direct antiglobulin testing normally shows IgG on the erythrocyte surface in cases of the warm antibody type, but not in cold antibody-mediated disease (3, 4). A positive test for complement protein C3d and if relevant C3c shows

complement activation, which is always present in cases of autoimmune haemolytic anaemia of the cold antibody type.

The assessment was now that the child had haemolytic anaemia as a complication of infection. New blood tests in the evening showed a further fall in the haemoglobin level from 7.0 g/dl to 6.3 g/dl. This was regarded as probable dilution following addition of fluid. On day 2 after his admission, the boy's general condition was good, but his pulse rose to 140–150/min in connection with activity. He was reluctant to urinate because of the pain. His urine was cola-coloured, without coagula. The boy was distinctly icteric, but was assessed as being clinically stable, and it was decided to hold off on blood transfusion.

Autoimmune haemolytic anaemia may be primary or secondary to other conditions, most frequently lymphoproliferative disease or an autoimmune condition such as systemic lupus erythematosus, rheumatoid arthritis etc. The condition may also be triggered by antibiotics or non-steroidal anti-inflammatory drugs. In some cases, an acute infection may be the cause of the condition. In a French cohort study with 265 children with autoimmune haemolytic anaemia, the condition was post-infectious in 10 %, associated with another immunological disease in 53 % and primary in 37 % of the cases (2).


On the third day his general condition had deteriorated, and the boy was now complaining of pain in his joints and head. He was pale and had increasing tachycardia with a pulse of 150/min and blood pressure 74/33 mm Hg. New blood tests showed haemoglobin 4.6 g/dl, and he received a transfusion of erythrocytes 5 ml/kg using a blood warmer. The cause of the autoimmune haemolytic anaemia was now reassessed. A number of conditions were considered, including autoimmune diseases, malignancy and immune defects such as autoimmune lymphoproliferative syndrome (ALPS) or severe combined immune deficiency (SCID). The possibility that the condition might be due to infection or triggered by mecillinam therapy had not been excluded. The following were ordered: rheumatology tests, blood tests for Epstein-Barr virus, cytomegalovirus and parvovirus, testing of a nasopharyngeal specimen for *Mycoplasma pneumoniae*, a gastrointestinal pathogen panel, and lymphocyte quantification and flow cytometric subclassification of blood lymphocytes. After conferring with the Department of Immunology and Transfusion Medicine, cold agglutinin titration was ordered, as secondary cold agglutinin syndrome was a possible differential diagnosis. After transfusion, Hb rose to 7.3 g/dl.

In autoimmune haemolytic anaemia of the cold antibody type, the autoantibody very often causes agglutination of red blood cells and is then referred to as a cold agglutinin. Cold agglutinins bind to surface antigen I or i on the erythrocytes (4, 5). Primary cold agglutinin disease is caused by lymphoproliferative bone marrow disorder, but is not found in children. Secondary cold agglutinin syndrome may be due to *Mycoplasma pneumoniae* or Epstein-Barr virus, for example. In these conditions, in addition to a positive direct antiglobulin test for C3d, a cold agglutinin titre of at least 64, and often far higher, is also found (4, 5).

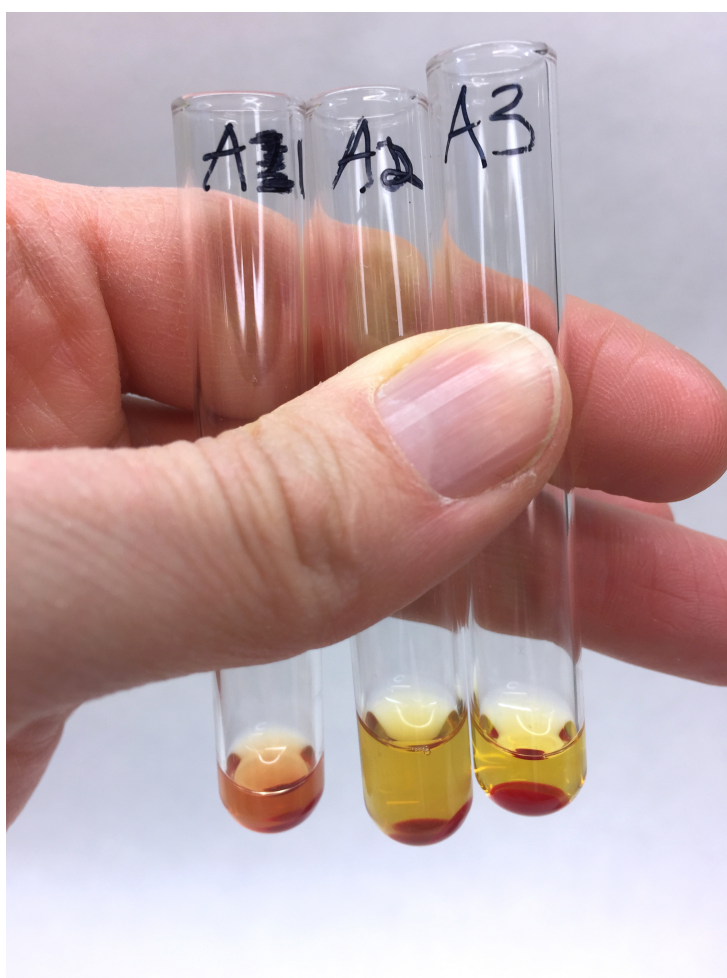
Over the next few days, his haemoglobin level fell again, to 6.3 g/dl. Cold agglutinin titration revealed a titre of < 4 (< 32), and this was not consistent with cold agglutinin syndrome. A new, comprehensive assessment of the clinical findings and analytical results led to the conclusion that they might be consistent with an unusual diagnosis, paroxysmal cold haemoglobinuria.

Paroxysmal cold haemoglobinuria is a rare type of autoimmune haemolytic anaemia. Haemolysis is due to a biphasic IgG autoantibody that can be detected by means of a special laboratory test, the Donath-Landsteiner test.

Owing to strong clinical suspicion of paroxysmal cold haemoglobinuria, a Donath-Landsteiner test was ordered. The test had only been carried out at the laboratory a couple of times before, and the test procedure was acquired and reviewed by doctors and bioengineers (6). The test was clearly positive, and confirmed the condition (Figs 1, figs 2). Neither a triggering agent nor an underlying disease was detected.



**Figure 1** The whole set-up for the Donath-Landsteiner test. There is haemolysis in test tube A<sub>1</sub>, which is consistent with a positive test.



**Figure 2** Haemolysis in test tube A<sub>1</sub> is consistent with a positive Donath-Landsteiner test.

After the diagnosis had been made, the boy was kept away from the cold, cold drinks and ice cream, and no further haemolysis occurred. His general condition gradually improved. His haemoglobin level rose over the next couple of days to 7.7 g/dl, and there was considerable reticulocytosis. Nine days after admission he was discharged in good health, with the option to return at any time in the event of new anaemia symptoms. Weekly check-ups were agreed upon, with haematology tests, haemolysis tests (Table 1) and a direct antiglobulin test. The parents were instructed that the child should avoid exposure to the cold.

**Table 1**

Changes in haemolysis parameters in the course of the condition

	Haemoglobin (g/dl)	Bilirubin ( $\mu$ mol/l)	Lactate dehydrogenase (U/l)
Day -1	11.4	-	-
Day 1	7.0	75	Not analysed because of haemolysis
	6.6		
	6.3		
Day 2	6.0	40	1745
	6.5	25	1592
Day 3	4.6	11	1206
Follow-up after blood transfusion	7.3		
Day 4	6.6	21	
Day 5	6.3	6	863
Day 6	6.8	9	739
Day 7	7.7		
Day 8	7.7	7	
Day 9 Discharge	8.6		
Day 17	11.3	3	
Day 24	12.5		
Day 43	13.7		

At follow-up eight days after discharge, his haemoglobin level was 11.3 g/dl. Haptoglobin was 0.26 g/l and a direct antiglobulin test was still positive for C3d. Lactate dehydrogenase and bilirubin were normalised. The results of complement factor testing while he was in hospital were now available and showed C3 1.19 g/l (0.83–1.65 g/l), C4 0.2 g/l (0.13–0.36 g/l) and haemolytic activity/CH50 showed 10–50 %, which is somewhat reduced.

The direct antiglobulin test was not negative until six weeks after the onset of the illness, at which point a cold provocation test was conducted. The child was allowed to go outside in 5–10 °C for 10–20 minutes and to eat an ice cream. He was then observed in the department. His haemoglobin remained stable at 13.7 g/dl, and urine dipsticks were negative. At an assessment two days later there was still no clinical change, blood tests were normal and the child was viewed as well.

## Discussion

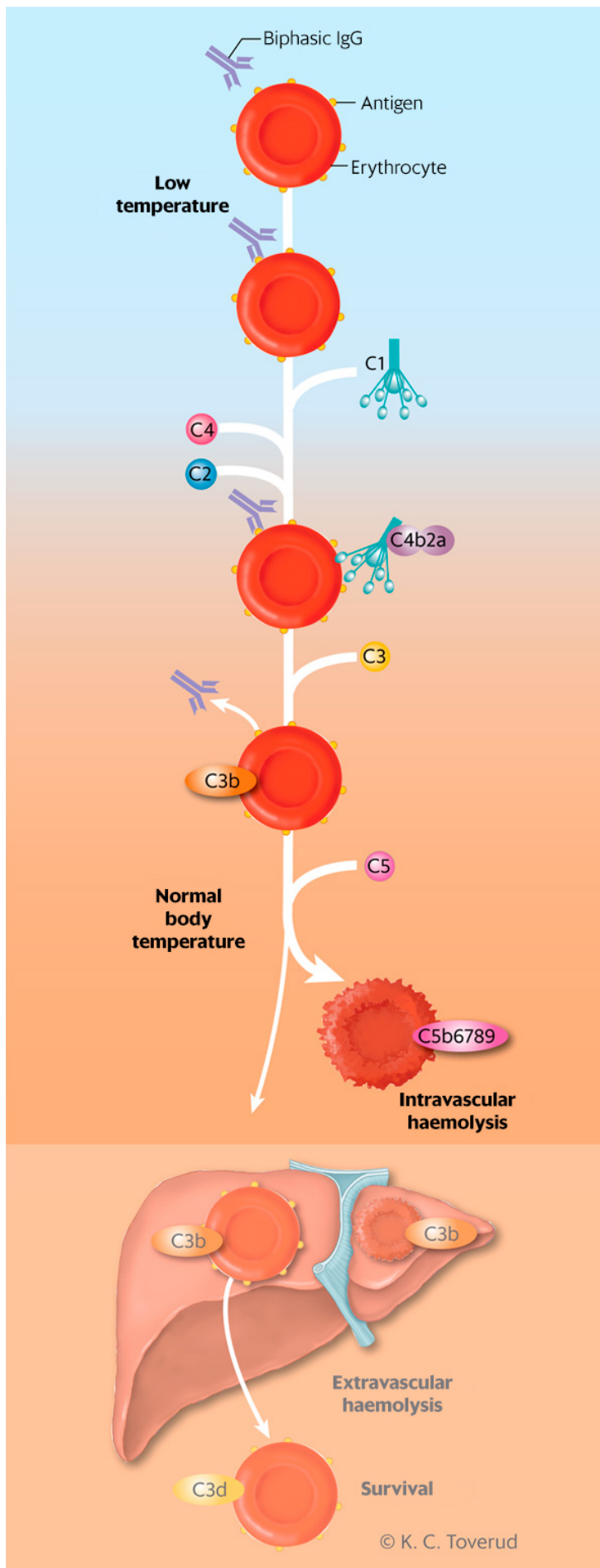
This case history describes an unusual cause of anaemia. The cold antibody type of autoimmune haemolytic anaemias accounts for 25 % of cases and consists of primary chronic cold agglutinin disease, secondary cold agglutinin syndrome and paroxysmal cold haemoglobinuria. The first two were recently discussed in the Journal of the Norwegian Medical Association and will not be described here (5). A major French cohort study found the cold antibody type in 11 % of children with autoimmune haemolytic anaemia (2).

Paroxysmal cold haemoglobinuria, first described by Julius Donath and Karl Landsteiner in 1904 (7), occurs extremely rarely in adults, but has been assumed to account for 1–5 % of cases of autoimmune haemolytic anaemia in children (4, 8). In recent years, a number of studies have reported a higher incidence, up to 32 % of the cases of haemolytic anaemia in children (9). This may well be due to an increased focus on the diagnosis and a more readily available Donath-Landsteiner test (8). The condition usually occurs in small children (median age five years), but has been reported in all age groups and is more common in boys (boy:girl ratio 2:1) (8).

The onset of paroxysmal cold haemoglobinuria in children normally occurs 1–2 weeks after an infection, usually an upper respiratory tract infection. A number of aetiological agents

have been described, including varicella virus, parvovirus, Epstein-Barr virus, cytomegalovirus, adenovirus, *Mycoplasma pneumoniae* and *Haemophilus influenzae* (8, 10). In many cases, efforts to detect an aetiological agent fail.

Pathogenesis takes the form of a polyclonal IgG autoantibody binding to the P-antigen on the surface of erythrocytes at temperatures lower than normal core body temperature. These temperatures are normally found in the face and extremities in cold surroundings or in the upper gastrointestinal canal when a cold drink or ice cream is ingested (10). After warming up, the antigen-antibody complex will activate the complement system, and the result is intravascular haemolysis (Fig. 3).



**Figure 3** Complement-mediated haemolysis induced by biphasic IgG (Donath-Landsteiner antibody). At sub-normal core body temperatures, the antibody binds to the erythrocyte surface. The antigen-antibody complex binds complement protein complex C1, which then fixes and activates C2 and C4. After warming to 37 °C in the body core, C3 binds and splits. This leads to further activation of the

classical pathway, while IgG is now released from the cell surface. Subsequent binding and splitting of C<sub>5</sub> activates the terminal complement cascade with formation of the membrane attack complex (C<sub>5b</sub>6789) and intravascular haemolysis. C<sub>3b</sub>-opsonised erythrocytes are also phagocytosed, to a lesser extent, in the mononuclear phagocyte system (extravascular haemolysis). C<sub>3b</sub> on surviving erythrocytes splits into inter alia C<sub>3c</sub> and C<sub>3d</sub>, which can be detected by a direct antiglobulin test (DAD) (3).

Anaemia symptoms predominate in the clinical picture, frequently with icterus and haemoglobinuria. Episodes of intravascular haemolysis will often manifest as abdominal pain, fever and cola-coloured urine. Palpable liver and spleen have been described in 25 % of cases in children, and leukocytosis occurs frequently (8).

In laboratory terms, haemolytic anaemia occurs with low haemoglobin and haptoglobin and high lactate dehydrogenase and bilirubin. In many cases, the haemoglobin level is very low, often less than 5 g/dl. Bone marrow compensation usually causes reticulocytosis, as in our patient, but reticulocytopenia may also occur. Blood smears may show spherocytes, anisocytosis and polychromasia, but to a lesser extent than in autoimmune haemolytic anaemia of the warm antibody type (10). A direct antiglobulin test is usually IgG negative because the autoantibody is eluted in the pathogenic process, but is almost always positive for C<sub>3d</sub> and often for C<sub>3c</sub> because of complement activation (3, 10).

The diagnosis is confirmed by means of the Donath-Landsteiner test (Table 2). The method was first described in 1904, and is very specific (10). However, sensitivity is limited, and false negative results are obtained relatively often, because the patient's blood has little residual complement. In order to increase sensitivity, complement in the form of normal fresh serum can be added to the sample. A Donath-Landsteiner testing procedure has now been introduced in our laboratory.

**Table 2**

The purpose of the Donath-Landsteiner test is to confirm that there is an IgG autoantibody of the type biphasic haemolysin that binds to erythrocytes at low temperatures (4 °C), whereas haemolysis only takes place when the sample is incubated at a warm temperature. The test is conducted on a fresh serum sample that is separated when warm. Washed P-positive erythrocytes (sample from blood donor) are added to the patient's serum in three parallel batches (test tubes A<sub>1-3</sub>, B<sub>1-3</sub> and C<sub>1-3</sub>). The test is positive if the patient's serum with or without added complement (normal serum) causes haemolysis in one or both test tubes which have been incubated first on ice and then at 37 °C (A<sub>1</sub> and A<sub>2</sub>). There should not be haemolysis in any of the other test tubes (6).

Test tube marked A	Test tube marked B	Test tube marked C
Ice bath for 30 minutes 37 °C for 60 minutes	Ice bath for 90 minutes	37 °C for 90 minutes
A1 Patient serum P+ cells	B1 Patient serum P+ cells	C1 Patient serum P+ cells
A2 Patient serum Normal serum P+ cells	B2 Patient serum Normal serum P+ cells	C2 Patient serum Normal serum P+ cells
A3 Normal serum P+ cells	B3 Normal serum P+ cells	C3 Normal serum P+ cells

Paroxysmal cold haemoglobinuria is normally self-limiting, and the main treatment consists of preventing exposure to the cold as long as the autoantibody is active. In the acute phase, however, haemolysis can be serious and happen rapidly, with a substantial fall



in haemoglobin in a short period. Deaths have been reported (8). There will usually be a need for transfusions. Special precautions should be taken during the transfusion, and the use of a blood warmer is recommended. The patient must be kept warm and must not be given the transfusion in a cold extremity (4). The condition will resolve spontaneously after a few weeks in most cases. Recurrence or a chronic course is very rare, and has mainly been described in adults with underlying malignancy (11). Corticosteroids have not been found to be efficacious, while rituximab and eculizumab have been tried in some cases, with varying efficacy (3, 10).

## Conclusion

Paroxysmal cold haemoglobinuria is a rare form of post-infection anaemia in children. The Donath-Landsteiner test is diagnostic. All patients with autoimmune haemolytic anaemia must be tested in detail to determine the subtype, as this classification has crucial implications for therapy.

---

### REFERENCES:

1. Norsk barnelegeforening. Akuttveileder i pediatri. Utg. 2013–2015. <https://www.helsebiblioteket.no/pediatriveiledere> (30.11.2018).
2. Centre de Référence National des Cytopenies Auto-immunes de l'Enfant (CEREVANCE). New insights into childhood autoimmune hemolytic anemia: a French national observational study of 265 children. *Haematologica* 2011; 96: 655–63. [PubMed][CrossRef]
3. Berentsen S. Role of complement in autoimmune hemolytic anemia. *Transfus Med Hemother* 2015; 42: 303–10. [PubMed][CrossRef]
4. Berentsen S, Sundic T, Hervig T et al. Autoimmun hemolytisk anemi. *Tidsskr Nor Legeforen* 2009; 129: 2226–31. [PubMed][CrossRef]
5. Nordtveit S, Lerum TV, Ghanima W et al. En mann i 50-årene med feber og anemi. *Tidsskr Nor Legeforen* 2018; 138. doi: 10.4045/tidsskr.17.0460. [PubMed][CrossRef]
6. Fung MK, red. Technical Manual. 19. utg. Bethesda, MD: AABB, 2017: 400–1.
7. Donath J, Landsteiner K. Ueber paroxysmale Hämoglobinurie Muenchener medizinische Wochenschrift 1904; 36: 1590–3.
8. Petz LD. Cold antibody autoimmune hemolytic anemias. *Blood Rev* 2008; 22: 1–15. [PubMed][CrossRef]
9. Götsche B, Salama A, Mueller-Eckhardt C. Donath-Landsteiner autoimmune hemolytic anemia in children. A study of 22 cases. *Vox Sang* 1990; 58: 281–6. [PubMed][CrossRef]
10. Shanbhag S, Spivak J. Paroxysmal cold hemoglobinuria. *Hematol Oncol Clin North Am* 2015; 29: 473–8. [PubMed][CrossRef]
11. Prince SD, Winestone LE, Nance SJ et al. Recurrent Donath-Landsteiner hemolytic anemia: a pediatric case report. *Transfusion* 2017; 57: 1401–6. [PubMed][CrossRef]

---

Published: 25 March 2019. *Tidsskr Nor Legeforen*. DOI: 10.4045/tidsskr.18.0532

Received 20.6.2018, first revision submitted 30.11.2018, accepted 7.12.2018.

© The Journal of the Norwegian Medical Association 2020. Downloaded from [tidsskriftet.no](http://tidsskriftet.no)