



Pulmonary embolism in cases of COVID-19

KORT KASUISTIKK

ANDERS TVEITA

E-mail: andaun@vestreviken.no
Department of Internal Medicine
Bærum Hospital
and

K.G. Jebsen Centre for B cell malignancies
Oslo University Hospital

Anders Tveita PhD is a specialty registrar and researcher.

The author has completed the ICMJE form and declares no conflicts of interest.

SIV HESTENES

Department of Anaesthesia, Intensive Care, General Surgery and Acute Admissions
Bærum Hospital

Siv Hestenes is a senior consultant and specialist in anaesthesiology.

The author has completed the ICMJE form and declares no conflicts of interest.

EIRIK ROBSAHM SPORASTØYL

Department of Internal Medicine
Bærum Hospital

Eirik Robsahm Sporastøyl is a specialty registrar.

The author has completed the ICMJE form and declares no conflicts of interest.

STIAN ALEKSANDER PETTERSEN

Department of Diagnostic Imaging
Bærum Hospital

Stian Aleksander Pettersen is a specialty registrar in the Radiology Section.

The author has completed the ICMJE form and declares no conflicts of interest.

BENTE LUND NEPLE

Department of Diagnostic Imaging
Bærum Hospital

Bente Lund Neple is a specialist in radiology and senior consultant/head of the Radiology Section.

The author has completed the ICMJE form and declares no conflicts of interest.

MARIUS MYRSTAD

Department of Internal Medicine
Bærum Hospital

Marius Myrstad PhD is a senior consultant and specialist in internal medicine and geriatrics.

The author has completed the ICMJE form and declares no conflicts of interest.

ARNLJOT TVEIT

Department of Medical Research Bærum Hospital
and
Institute of Clinical Medicine
University of Oslo
Arnlfjot Tveit is head of department and adjunct professor.
The author has completed the ICMJE form and declares no conflicts of interest.

HEGE FRØEN

Department of Internal Medicine
Bærum Hospital
Hege Frøen is a specialist in internal medicine and haematology, and senior consultant/head of the Haematology Section.
The author has completed the ICMJE form and declares no conflicts of interest.

JAN SVENDSEN

Department of Internal Medicine
Bærum Hospital
Jan Svendsen is a specialist in internal medicine and infectious diseases, and senior consultant in the Infectious Diseases Section.
The author has completed the ICMJE form and declares no conflicts of interest.

ELSE JOHANNE RØNNING

Department of Internal Medicine
Bærum Hospital
Else Johanne Rønning is a specialist in internal medicine and infectious diseases, and senior consultant/head of the Infectious Diseases Section.
The author has completed the ICMJE form and declares no conflicts of interest.

BACKGROUND

Emerging reports indicate a high incidence of venous thromboembolism in patients hospitalised for SARS-CoV-2 pneumonia during the spring 2020 pandemic. The pronounced pulmonary and systemic inflammatory responses observed in these patients may contribute to a transient hypercoagulable state. In this setting, pulmonary embolism may cause further respiratory distress and clinical deterioration.

CASE PRESENTATION

We describe the clinical course of three patients admitted with SARS-CoV-2 infection and respiratory distress, where pulmonary embolism was detected during the course of the hospitalisation. Two of the cases occurred despite early institution of standard dosage of low molecular weight heparin thromboprophylaxis, and in one case, pulmonary embolism was diagnosed during the convalescent phase of an otherwise benign COVID-19 disease course.

INTERPRETATION

These cases highlight the importance of awareness of the potentially increased incidence of venous thromboembolism in COVID-19 disease. Further research is required to establish appropriate clinical management guidelines for prevention of thromboembolic complications in COVID-19.

Here we describe pulmonary embolism in three patients at different stages of COVID-19. The development of pulmonary embolism can be easy to overlook if respiratory failure and hypoxemia are attributed to SARS-CoV-2 pneumonia.

The clinical picture associated with COVID-19 is complicated by severe acute phase reactions and widespread inflammation in the lungs. Pulmonary embolism can also occur

in COVID-19 patients who receive thromboprophylaxis with low molecular weight heparin, and infection control considerations should not be an obstacle to essential diagnostic imaging.

Patient 1

A man in his seventies with type 2 diabetes was hospitalised after three days of fever with lower back and abdominal pain. Upon admission, he was found to have respiratory alkalosis and mild tachypnoea. A chest X-ray showed subtle opacities in basal areas of the right lung, suggestive of pneumonia. SARS-CoV-2 was detected in bronchial secretions. The patient remained tachypnoeic despite receiving supplemental O₂ at 2 l/min. He was also given enoxaparin 40 mg × 1 as thromboprophylaxis. A chest X-ray on day 4 revealed increased opacities bilaterally, which had progressed further by day 8.

From day 9, the patient showed increasing oxygen demand, and required 10 l/min via a non-rebreathing mask to maintain SpO₂ > 94 %. He was gradually becoming increasingly tired and weak. A chest X-ray on day 12 showed the lung opacities to be largely unchanged. Owing to a lack of improvement in oxygenation and a strong and sustained increase in D-dimer levels to > 10 mg/ml (Figure 1), CT pulmonary angiography was performed on day 15. This revealed bilateral segmental and subsegmental pulmonary embolisms, in addition to widespread infection-related opacities (Figures 2a–b). After initiation of anticoagulation therapy (enoxaparin 100 mg × 2), the patient's oxygen demand slowly decreased and his general condition rapidly improved.

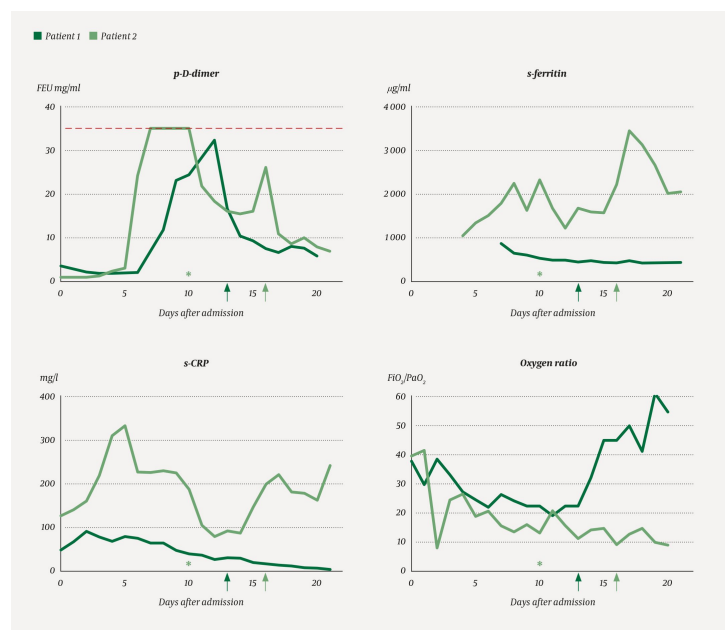


Figure 1 Timeline for levels of D-dimer (fibrinogen equivalent units, FEU) in plasma (p) and ferritin and C-reactive protein (CRP) in serum (s) in patients 1 and 2. The x-axis shows the number of days after hospitalisation. The dashed line indicates D-dimer levels > 35.2 mg/l, beyond which no further dilutions for quantitation were performed. D-dimer levels showed marked dynamic variation in both patients over the disease course, with an increase to double-digit values prior to CT angiography and discovery of the pulmonary embolisms (arrows). * indicates the point at which immunomodulatory therapy (anakinra) was initiated in patient 2. This was attempted owing to greatly elevated ferritin levels and persistently high D-dimer. A rapid decline in inflammation parameters was observed after the start of treatment, but without any significant improvement in clinical condition. The lower right panel shows the P/F oxygen ratio, which represents the patients' oxygen demand over the disease course. This is the ratio of the oxygen pressure in arterial blood (PaO₂) to the fraction of inspired oxygen (FiO₂). For patient 1, PaO₂ has been estimated from the oxygen saturation measured by pulse oximetry by means of a conversion table.

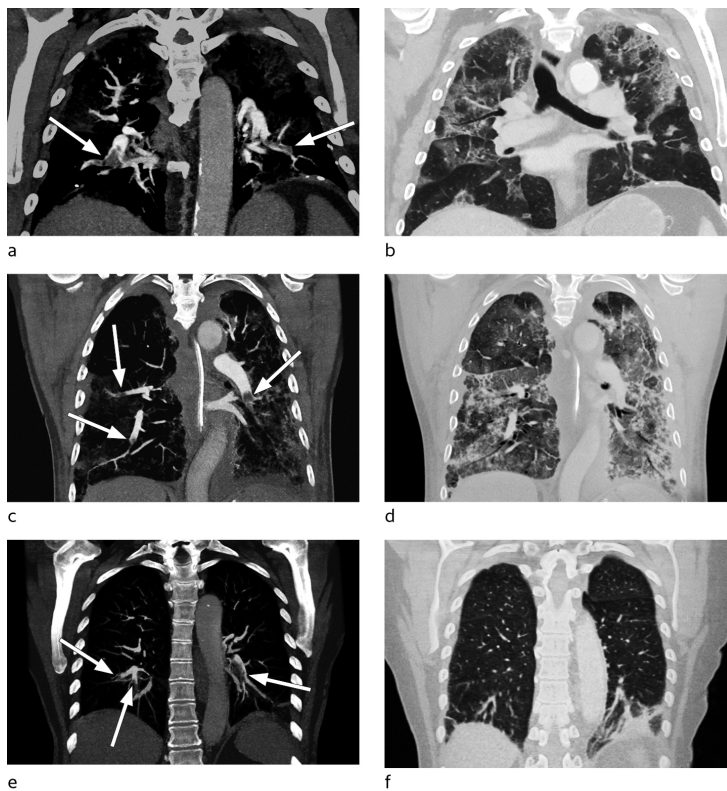


Figure 2 CT pulmonary angiography with coronal maximum intensity projection (MIP) reconstructions. The images show pulmonary embolisms in lower lobe pulmonary arteries in all three patients (a, c, e, arrows). Patients 1 (a, b) and 2 (c, d) also had bilateral opacities with features consistent with an infectious origin and a largely peripheral distribution that can be seen more clearly in the lung window (b, d). In patient 3 (e, f), a broad-based, rounded consolidation can be seen against the pleura at the base of the left lower lobe, most consistent with pulmonary infarction (f). Ground-glass opacities can be seen around the infarct, lungs are otherwise clear.

Patient 2

A previously healthy man in his late seventies was hospitalised after three days of high fever, dry cough and reduced general condition. He was not dyspnoeic, but had hypoxemia with SpO₂ 90 % in room air. A chest X-ray upon admission was normal. SARS-CoV-2 was detected in bronchial secretions. He was given enoxaparin 40 mg × 1 as thromboprophylaxis. A further chest X-ray on day 1 revealed new bilateral opacities. By day 2, he was weaker and showed greater oxygen demand. He became tachypnoeic on day 3, and an X-ray showed progression of the pulmonary opacities. He was transferred to the intensive care unit and intubated.

Based on reports of increased incidence of venous thromboembolism in intensive care patients with COVID-19, we decided to increase the prophylactic dose of enoxaparin to 40 mg × 2. On day 7, the patient's D-dimer levels increased from 2.8 to 24 mg/l. His ferritin level was > 2 000 µg/ml and treatment with an interleukin-1 receptor antagonist (anakinra) was initiated on day 10. Radiological progression of the pulmonary opacities was seen up to day 13, while D-dimer levels decreased after initiation of anakinra (Figure 1). However, owing to a renewed increase in D-dimer from 16 mg/ml to 26 mg/ml, CT pulmonary angiography was performed on day 16. This revealed bilateral peripheral pulmonary embolisms and widespread opacities in all lobes (Figures 2c-d). Anticoagulation therapy (enoxaparin 100 mg × 2) was initiated, but after a long disease course with severe respiratory failure that did not improve, the patient died on day 22.

Patient 3

A previously healthy woman in her seventies experienced a week of illness with mild dry

cough and upper respiratory tract symptoms. SARS-CoV-2 was detected in bronchial secretions after two days. After being free of symptoms for two weeks, the patient again developed a dry cough and was hospitalised 23 days after symptom onset, with activity-related dyspnoea and tachypnoea. Upon admission, she had respiratory alkalosis and a D-dimer level of 1.9 mg/ml. Chest X-ray was normal. CT pulmonary angiography was performed, and revealed bilateral segmental and subsegmental pulmonary embolisms affecting all lobes, but no opacities suggestive of infection (Figures 2e-f). She received oral anticoagulant therapy (apixaban 10 mg × 2) and was discharged when she showed improvement.

Discussion

These case studies demonstrate that pulmonary embolism may contribute to hypoxemia at various stages of the disease resulting from SARS-CoV-2 infection. It is difficult to pinpoint exactly when in the disease course this complication arose. In patients 1 and 2, high D-dimer levels were first attributed to a strong acute phase response to the infection (Figure 1). As the patients had been treated with low molecular weight heparin throughout their time in hospital, pulmonary embolism was not suspected until later in the disease course. Several studies have reported that high D-dimer levels (> 1.0 mg/ml) upon admission are associated with increased risk of death from COVID-19 (1-3), but the causal relationship is likely to be multifactorial.

In patient 2, a sharp rise in serum levels of C-reactive protein (CRP) and ferritin (Figure 1) was observed in the course of the disease. It has been reported that severe disease related to the coronavirus may be associated with the emergence of a hyperinflammatory state (cytokine storm) as part of the immune response to the virus (4), and there has been speculation over whether immunomodulatory therapy may be helpful in this regard. Given our patient's severe and persistent respiratory failure, we therefore decided to try immunomodulatory therapy with anakinra. After treatment initiation, we observed rapidly decreasing levels of D-dimer, CRP and ferritin (Figure 1), but no sign of any clinically significant improvement. This, in conjunction with a renewed increase in the D-dimer level, raised suspicion of pulmonary embolism.

In many patients COVID-19 leads to a prolonged disease course with high fever, reduced general condition and pulmonary involvement, all of which contribute to immobilisation. Treatment in intensive care in itself represents a significant risk factor for thromboembolic disease. Acute infections are associated with a significant but transient increase in the risk of venous thromboembolic events (5). Understanding of the pathophysiology of COVID-19-associated thromboembolic disease is still limited. Both the viral infection itself and the accompanying antiviral immune response entail a risk of vigorous activation of the coagulation system as a result of endothelial damage, platelet activation, and the release of potent proinflammatory cytokines (6). It is also suspected that endothelial damage may result in marked complement activation, thereby triggering a thrombotic microangiopathy similar to that seen in atypical haemolytic-uraemic syndrome (7). The high incidence of pulmonary embolism in cases of COVID-19 is presumably due to a combination of inflammation-mediated damage to pulmonary tissue (3) and systemic hypercoagulability.

Several publications have reported a strikingly high incidence of pulmonary embolism in COVID-19 patients. The condition has been detected in 20-30 % of patients in whom CT pulmonary angiography was performed on the basis of clinical indication (8-11). Biochemical and functional signs of hypercoagulability have been described in seriously ill COVID-19 patients and seem to be associated with a poor prognosis (1, 2, 8, 12, 13).

Among 184 intensive care patients in the Netherlands, 27 % had CT/ultrasound-confirmed venous thromboembolic events, 81 % of whom (25 patients) had pulmonary embolism (8). Deep vein thrombosis (DVT) was detected in one patient. Increased global coagulation parameters (INR, activated partial thromboplastin time) were predictors of

thromboembolic complications. This suggests that coagulopathy may contribute to the development of pulmonary embolism in cases of COVID-19 (8). It is worth noting that these patients received thromboprophylaxis with low molecular weight heparin. However, the doses differed across the various hospitals in the study, and also increased over time according to the article. At one of the centres, the prophylactic dose was doubled over the course of the observation period to two daily doses, and the authors argue in light of the strikingly high incidence of pulmonary embolism that this practice must be considered for intensive care patients with COVID-19 (8).

In the Dutch study, diagnostic imaging was performed only on clinical suspicion, and the overall incidence of thromboembolic disease may therefore be even higher (8). In seven of 25 patients with pulmonary embolism, only subsegmental embolisms were found. The clinical consequences of such peripheral thrombosis probably vary, depending on the extent of the infection-triggered parenchymal damage.

We have been informed by infectious disease and intensive care communities in Norway that a strikingly high incidence of thromboembolic complications has also been observed in COVID-19 patients here, despite the use of standard prophylactic doses of low molecular weight heparin (at our hospital, enoxaparin 40 mg \times 1). Based on this information and our own experience, we have decided to use an increased prophylactic dose of enoxaparin (40 mg \times 2) for some of these patients in our department. Systematic studies of the incidence of deep vein thrombosis and pulmonary embolism will be valuable for revealing the extent of such disease in hospitalised COVID-19 patients and for clarifying the underlying pathophysiology.

In our hospital, CT scans have only been used to a very limited degree for routine diagnostics in COVID-19 patients, primarily because inflammatory changes can readily be seen on a standard chest X-ray, but also because of infection control considerations. In view of the high incidence of pulmonary embolism in this patient group, more widespread use of CT angiography should be considered in patients with persistently high oxygen demand and biochemical signs of hyperinflammation, as well as in the event of D-dimer levels that are either very high or show marked variation.

Conclusion

Physicians who manage patients with COVID-19 both in and outside hospitals must be alert to the high incidence of thromboembolic complications in this patient group. Effective prophylaxis and rapid detection of any pulmonary embolisms will probably enable more patients to be treated successfully. CT pulmonary angiography should therefore be considered for patients with severe disease even if they are already being treated with low molecular weight heparin.

With limited understanding of the underlying pathophysiology and an absence of data from randomised controlled trials, it is difficult to formulate guidelines for thromboprophylaxis in cases of COVID-19. The incidence of bleeding complications should also be further surveyed. Whether increased prophylactic or therapeutic doses of low molecular weight heparin are indicated for the entire patient population, or only for those groups of patients thought to be at particularly high risk, has still to be determined. While we await the results of systematic studies, clinical practice should be based on consensus and experience from different centres nationally and internationally.

REFERENCES:

1. Zhou F, Yu T, Du R et al. Clinical course and risk factors for mortality of adult inpatients with COVID-19 in Wuhan, China: a retrospective cohort study. *Lancet* 2020; 395: 1054–62. [PubMed][CrossRef]
2. Tang N, Li D, Wang X et al. Abnormal coagulation parameters are associated with poor prognosis in

- patients with novel coronavirus pneumonia. *J Thromb Haemost* 2020; 18: 844-7. [PubMed][CrossRef]
3. Fogarty H, Townsend L, Ni Cheallaigh C et al. COVID-19 coagulopathy in Caucasian patients. *Br J Haematol* 2020; 189: bjh.16749. [PubMed][CrossRef]
 4. Mehta P, McAuley DF, Brown M et al. COVID-19: consider cytokine storm syndromes and immunosuppression. *Lancet* 2020; 395: 1033-4. [PubMed][CrossRef]
 5. Smeeth L, Cook C, Thomas S et al. Risk of deep vein thrombosis and pulmonary embolism after acute infection in a community setting. *Lancet* 2006; 367: 1075-9. [PubMed][CrossRef]
 6. Giannis D, Ziogas IA, Gianni P. Coagulation disorders in coronavirus infected patients: COVID-19, SARS-CoV-1, MERS-CoV and lessons from the past. *J Clin Virol* 2020; 127: 104362. [PubMed][CrossRef]
 7. Campbell CM, Kahwash R. Will complement inhibition be the new target in treating COVID-19 related systemic thrombosis? *Circulation* 2020; 141: CIRCULATIONAHA.120.047419. [PubMed][CrossRef]
 8. Klok FA, Kruip MJHA, van der Meer NJM et al. Incidence of thrombotic complications in critically ill ICU patients with COVID-19. *Thromb Res* 2020; 191: S0049-3848(20)30120-1. [PubMed][CrossRef]
 9. Poissy J, Goutay J, Caplan M et al. Pulmonary embolism in COVID-19 patients: Awareness of an increased prevalence. *Circulation* 2020; 141: CIRCULATIONAHA.120.047430. [PubMed][CrossRef]
 10. Leonard-Lorant I, Delabranche X, Severac F et al. Acute pulmonary embolism in COVID-19 patients on CT Angiography and relationship to d-dimer levels. *Radiology* 2020; 295: 201561. [PubMed][CrossRef]
 11. Grillet F, Behr J, Calame P et al. Acute pulmonary embolism associated with COVID-19 pneumonia detected by pulmonary CT angiography. *Radiology* 2020; 295: 201544. [PubMed][CrossRef]
 12. Ranucci M, Ballotta A, Di Dedda U et al. The procoagulant pattern of patients with COVID-19 acute respiratory distress syndrome. *J Thromb Haemost* 2020; 18: jth.14854. [PubMed][CrossRef]
 13. Panigada M, Bottino N, Tagliabue P et al. Hypercoagulability of COVID-19 patients in Intensive Care Unit. A Report of Thromboelastography Findings and other Parameters of Hemostasis. *J Thromb Haemost* 2020; 18: jth.14850. [PubMed][CrossRef]

Published: 13 May 2020. Tidsskr Nor Legeforen. DOI: 10.4045/tidsskr.20.0366

Received 23.4.2020, first revision submitted 1.5.2020, accepted 4.5.2020.

© The Journal of the Norwegian Medical Association 2020. Downloaded from tidsskriftet.no