

# Bariatric surgery in inflammatory bowel disease

Surgical treatment of morbid obesity in patients with inflammatory bowel disease is a difficult issue. There are very few references to this subject in the literature, which may mean that little is known about this problem. Serious complications are feared with this type of surgery in these patients, and interdisciplinary cooperation between gastroenterologists and gastric surgeons is therefore important. Here we have described a case history from our own practice.

**Bjørn Moum**  
 bjorn.moum@medisin.uio.no  
**Jørgen Jahnsen**  
 Department of Gastroenterology  
 Oslo University Hospital, Aker  
 Trondheimsv. 235  
 NO-0514 Oslo

Obesity is rare as a clinical problem in patients with inflammatory bowel disease (Crohn's disease and ulcerative colitis) as malabsorption is often a feature of these diseases. However, there are some patients with both inflammatory bowel disease and obesity who want bariatric surgery because they have not succeeded in losing weight with diet. Patients with Crohn's disease and ulcerative colitis run an increased risk of postoperative complications caused by the immunosuppressive drugs used to treat the bowel disease. Aggravation of malabsorption and poorer results of surgery are other relevant issues in these patients. The fol-

lowing case history illustrates some of these questions.

*In 2004 ileocolic Crohn's disease was diagnosed in a 40 year old woman, after one year of increasing diarrhoea, abdominal pain and loss of weight. When the diagnosis was made, her body mass index (BMI) was 31.4 kg/m<sup>2</sup>. Initially she was treated with prednisolon with a good effect. After repeated unsuccessful attempts to stop treatment with corticosteroids, including giving supplementary azathioprin and later methotrexate, treatment with the TNF  $\alpha$  inhibitor infliximab was started. She rapidly became symptom-free and at the same time the calprotectin level (disease activity marker for inflammation in the bowel) in her faeces returned to normal (1). Prednisolon was discontinued after a short period. During the following years there was full remission of her bowel disease with maintenance therapy with infliximab combined with methotrexate. Ileocoloscopy carried out one year after starting infliximab showed endoscopically*

*and microscopically healed and normal mucosa. As a consequence of very good control of the disease, her weight increased, and in December 2008 her BMI was 45 kg/m<sup>2</sup>.*

*There was a familial aggregation of diabetes type 2, high blood pressure and hypercholesterolemia. The patient brought up the issue of bariatric surgery. We expressed our doubts about this because of lack of references in the literature and risk of complications in surgery of the small intestine. The patient understood this as a refusal by us, and on her own initiative she contacted a private clinic where a gastric bypass operation was carried out two months later with no complications. We saw the patient one week after the operation. She was then in good shape and had no bowel symptoms.*

*About 6–8 weeks after the operation she had gradually increasing abdominal pain and frequent bowel emptying with diarrhoea and mucus. There were increasing calprotectin levels in her faeces (highest level 814; normal < 100) as objective signs of active inflammation of the intestine. At the same time her CRP level increased from 29 mg/l to 79 mg/l and the leukocyte count increased to  $11.9 \times 10^9/l$ . Her weight had decreased by 18 kilos since the operation. High dose infliximab (10 mg/kg body weight) was given in two consecutive infusions at an eight weeks interval, first infusion three months after the operation. The clinical effect of this was good, and the levels of calprotectin and CRP gradually returned to normal. Eight months after the operation her BMI was 32.4 kg/m<sup>2</sup> (weight reduction from 130 kg to 96 kg), and the patient was very pleased with her situation.*

The same inflammation markers that are increased in obesity are also found in Crohn's disease and ulcerative colitis (2). The question of whether obesity can exacerbate the course of inflammatory bowel disease is therefore interesting. One report shows increased risk of perianal

**Table 1** Possible advantages and unfortunate side-effects connected with bariatric surgery in patients with inflammatory bowel disease (Crohn's disease and ulcerative colitis)

Possible advantages	Possible side-effects
<ul style="list-style-type: none"> <li>- Prevention of obesity-related diseases</li> <li>- Reduction of inflammation in intestinal disease, thereby decrease of disease activity and complications</li> </ul>	<ul style="list-style-type: none"> <li>- Exacerbation of intestinal disease (increased inflammatory activity, formation of new fistulas and abscesses in operated intestinal segment – particularly small intestine in Crohn's disease)</li> <li>- Complicated operation, complications and poor long-term result connected with colectomy with reservoir</li> <li>- Increased and difficult to control malabsorption in Crohn's disease in excess of the expected results of bariatric surgery</li> <li>- Increased risk of postoperative infection with preoperative immunosuppressive treatment of the intestinal disease (prednisolon, anti-TNF-<math>\alpha</math>)</li> <li>- Increased risk of cancer of the small intestine</li> </ul>

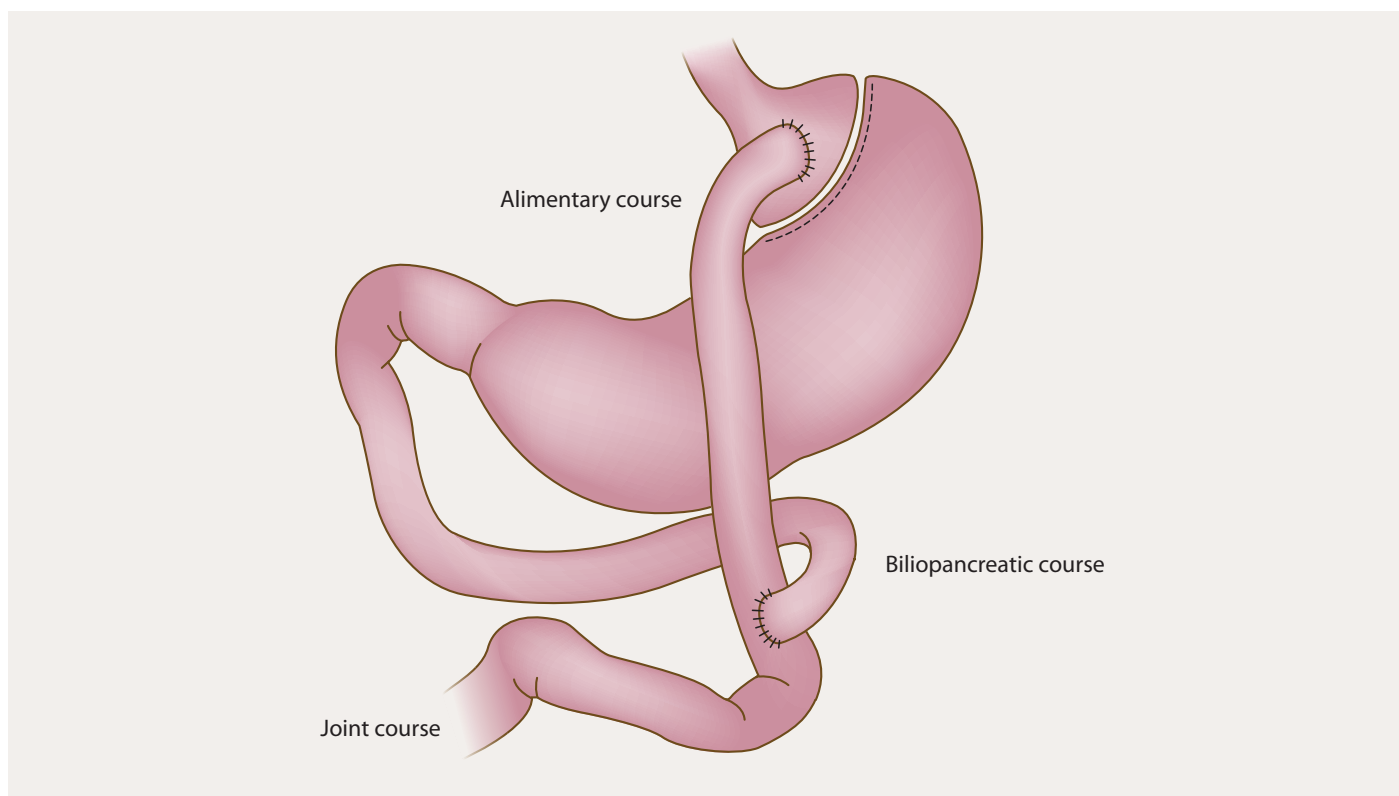


Illustration of procedure in bariatric surgery with Laparoscopic Roux-en Y Gastric Bypass (LRYGBP)

disease and disease activity over a period in patients with Crohn's disease and obesity compared with those with Crohn's disease and no obesity (3).

The patient contacted us because she was very worried by her considerable overweight, and about obesity-related diseases that she might develop. This is what convinced her to have an operation in spite of our scepticism. We have only found one report describing the connection between bariatric surgery and disappearance of bowel symptoms, return to normal of preoperative high blood pressure, and improvement of diabetes mellitus in a patient with ulcerative colitis (4). On the other hand, the patient was still taking a betablocker to control the blood pressure and continuous prednisolon and azatioprin to control the bowel disease one year after operation. Colonoscopy showed persistent active colitis.

Our patient developed recurrence of the disease a few weeks after bariatric surgery. Before this, her disease had been stable for about four years, since she started taking infliximab. The flare-up of the disease may have been by chance, a result of the stress of being operated, or caused by altered bacteria, fluid and electrolyte status in the digestive tract after the operation.

The risk of complications connected with bariatric surgery is different and probably more serious in a patient with Crohn's disease than in a patient with ulcerative colitis. Regardless of method, bariatric

surgery for morbid obesity will affect the segments of the intestine where the disease is located in most patients with Crohn's disease, i.e. parts of or the whole small intestine. There will therefore probably be an increased risk of a flare-up of the disease in the operated segment. The following complications may arise in connection with laparoscopic Roux-en-Y gastric bypass (LRYGBP): anastomatic strictures, ileus, and formation of fistulas and abscesses. This applies both to disconnected segments of the intestine and the site of reduction plasty of the stomach. It is an open question whether the lack of literature on this subject is because complications never occur. At best, the operation can prevent obesity-induced inflammation, which could theoretically exacerbate the intestinal disease (4).

There is an increased risk of complications connected with surgery of the gastrointestinal canal in patients with Crohn's disease when the operation is carried out for a different reason than the basic disease, for example bariatric surgery (5, 6) (tab 1). This risk is greatest when the small intestine is affected. It can therefore be proposed that surgery is only justified when Crohn's disease only affects the colon. Nevertheless, the least invasive operation for obesity should be chosen, and gastric reduction plasty should be sufficient. A more extensive operation on the small intestine such as laparoscopic Roux-en-Y gastric bypass may increase the malabsorption and risk of cancer in the small intestine because of

inflammation and formation of blind passages. Already existing diarrhoea due to malabsorption or previous colectomy will also be aggravated by the operation.

After bariatric surgery for inflammatory bowel disease, it may be more difficult to carry out subsequent operations for intestinal disease, particularly colectomy with reservoir formation. Disturbance of the anatomy of the small intestine and mesentery, scar formation and adhesions will probably decrease the chances of a good result. It is therefore important to select surgery with minimal invasive procedures to achieve weight reduction.

The surgery received by our patient will also increase the risk of postoperative infection because of use of the immunosuppressive treatment with a TNF- $\alpha$ -inhibitor (7), although this issue has been shown to apply most when higher supplementary doses of prednisolon are also given (8).

*The patient has given permission for the article to be published.*

*Reported conflicts of interest: None*

#### References

1. Jahnsen J, Røseth AG, Aadland E. Measurement of calprotectin in faeces. *Tidsskr Nor Lægeforen* 2009; 129: 743–5.
2. Das U. Is obesity an inflammatory condition? *Nutrition* 2001; 17: 953–66.
3. Blain A, Cattani S, Beaugerie L et al. Crohn's disease clinical course and severity in obese patients. *Clin Nutr* 2002; 21: 51–7.

>>>

4. Lascano CA, Soto F, Carrodeguas L et al. Management of ulcerative colitis in the morbidly obese patient: Is bariatric surgery indicated? *Obes Surg* 2006; 16: 783–6.
5. Tilney HS, Constantinides VA, Heriot AG et al. Comparison of laparoscopic and open ileocecal resection for Crohn's disease: a metaanalysis. *Surg Endosc* 2006; 20: 1036–44.
6. Stocchi L, Milsom JW, Fazio VW. Long-term outcomes of laparoscopic versus open ileocolic resection for Crohn's disease: follow-up of a prospective randomized trial. *Surgery* 2008; 144: 622–7.
7. Zeddy JG, Loftus EV. Safety of infliximab and other biologic agents in the inflammatory bowel diseases. *Gastroenterol Clin North Am* 2006; 35: 837–55.
8. Selvasekar CR, Cima RR, Larson DW et al. Effect of infliximab on short-term complications in patients undergoing operation for chronic ulcerative colitis. *J Am Coll Surg* 2007; 204: 956–62.

*Manuskriptet ble mottatt 26.10.2009 og godkjent 28.1.2010. Medisinsk redaktør Michael Bretthauer.*