

A fit man with fever and pain in both thighs

We present a typical course for an infectious disease that is seldom seen in Norway. The case history illustrates the fact that both the patient's account and a sound knowledge of unusual infectious diseases may be crucial for making the right diagnosis.

See Comment page 670

Marius Myrstad
 marius.myrstad@diakonsyk.no
Kiarash Tazmini
Knut Henrik Spæren
Aira Bucher
 Medical Department
 Diakonhjemmet Hospital

A fit man in his seventies arrived at Acute Admissions by ambulance because of severe pain in both thighs. The onset of the pain had been five days earlier, when the man was in the mountains hunting. The pain started as a diffuse ache in both thighs, and was first assumed to be stiffness after a long walk in the mountains. The pain became more intense, and the next day the man developed fever and urinated frequently in small quantities. On the third day he developed diarrhoea without abdominal pain. The pain in his thighs persisted, increased in intensity over the next few days and finally became so bad that the man rang for an ambulance because he had difficulty walking. Prior to this he had been unusually fit, and engaged in rowing and other competitive sport. Before he left for the mountains, he had just returned from a ten-day stay in southern France, where he had rowed on a river, among other things. The man had not been sick previously, did not use medicines and had not been to a doctor for many years.

When the patient was examined in Acute Admissions he was weak. His temperature, measured in his ear, was 39.0°C, pulse 80, blood pressure 140/90 and ECG showed sinus rhythm. The patient was not tender to palpation of the thigh musculature, but experienced severe pain in the thighs when he attempted to move. There were palpable and equal pulses in both groins and distally on the lower limbs. Skin colour and temperature were normal on both sides. There was no swelling of the legs. A wound without signs of infection was found on the man's right elbow. The man related that during the trip in southern France he had fallen and hit

his right elbow. After the fall he had a large lump on his elbow, and after a few days this spontaneously discharged a clear fluid. Apart from that the somatic and neurological examination was normal.

The patient was admitted with his condition undetermined and his main symptom severe pain in both thighs on attempts at movement. Stiffness is not unusual for the first few days following a long walk in the mountains. In this case, however, the pain increased in intensity over a period of several days and finally became so severe that it could not be explained on the basis of physical exertion. The patient also had a temperature, which initially caused a search for a focus of infection. A tumour over the right olecranon could have represented bursitis and thus a starting point for infection. Pollakisuria could be a symptom of a urinary tract infection. The patient had diarrhoea, but no other symptoms from the gastrointestinal canal, nor did he have any other specific symptoms indicating an infection focus.

General blood tests showed thrombocytes 32 (139–450 10⁹/l), sedimentation rate 46 (2–10 mm/hour), CRP 355 (0–10 mg/l), sodium 127 (137–145 mmol/l), potassium 3.2 (3.5–5.0 mmol/l), creatinine 257 (50–90 µmol/l), estimated glomerular filtration rate (eGFR) 21, urea 28.7 (3.0–8.0 mmol/l), AST 233 (15–35 U/l), ALT 146 (10–45 U/l), gamma-GT 83 (10–75 U/l), alkaline phosphatases 220 (35–105 U/l), CK 539 (35–210 U/l) and lactate dehydrogenase (LD) 380 (115–255). Other values were within the reference ranges. Arterial blood gases showed pH 7.53 (7.35–7.45), pO₂ 8.1 (11.0–14.0 kPa) pCO₂ 3.8 (4.7–6.0 kPa) and O₂ saturation 93 (94–99%), otherwise normal values. Chest X-ray was normal. Urine dipsticks showed white 2+, albumin 1+, blood 3+, nitrite and glucose were negative. Urine microscopy revealed moderate quantities of red and white blood cells and squamous epithelium.

It was striking that almost all blood samples were abnormal. A high CRP and sedimentation rate increased the suspicion of infection. Kidney failure and elevated liver test values indicated that the disease affected several organs, as one sees with sepsis. Hyponatraemia and hypokalaemia could be explained by gastrointestinal loss as a result of diarrhoea or renal loss. Severe pain may stimulate ADH secretion, which can result in hyponatraemia as a result of a dilution effect. Thrombocytopenia could be caused by bone marrow depression due to infection. Moderately elevated CK, LD and transaminases were consistent with a muscular disease, but there was still no definite explanation for the pain in the man's thighs.

In Acute Admissions, his condition was regarded as a bacterial infection with unknown focus. After blood and urine and faeces samples had been taken for culturing, treatment was started with ceftriaxone 2 g x 1, clear fluids intravenously and correction of the electrolyte imbalances. The patient became afebrile in the course of the first day, otherwise his condition changed little in the first two days after his admission. On the third day, the pain in his legs was less pronounced, his faeces had more shape and his general condition was appreciably improved. His CRP had fallen to 90. On the advice of the infectious diseases doctors in the department, blood samples were taken for hantavirus and leptospirosis serology testing.

Nephropathia epidemica was a possible differential diagnosis because the patient had recently been in the mountains. Fever, thrombocytopenia and renal failure could be consistent with this disease, which is due to infection with hantavirus and is transmitted through contact with small rodents. Like leptospirosis, nephropathia epidemica can cause pain, but usually located in the abdomen or back (1). The incubation period is normally at least a week, however, which made hantavirus infection less probable in this case. Muscular pain in combination with fever and thrombocytopenia is also typical of granulocytic ehrlichiosis, a tick-borne bacterial infection (2). However, this disease is very seldom seen in Norway, and our patient had not observed any tick bite.

Because of the travel history, infection with Rickettsia was also a possible differential diagnosis. Rickettsiosis is characterised by myalgia, severe headaches, fever and ex-

anthema. Both gastrointestinal symptoms and affection of kidney and liver function may occur with this group of infections, and exanthema may not be present (3). Nevertheless, the patient's account and the disease picture were most typical of leptospirosis. As the patient was improving, intravenous antibiotics treatment was discontinued and he was started on doxycycline tablets. The patient had spoken to a relative who had also been an active rower. She thought that the patient might have Weil's disease, which she herself had had previously. Weil's disease is the name of the severe form of leptospirosis. Fever, headache and myalgia are the most common symptoms of this form, but in 3–10 patients an initial septic phase is seen, where affection of the liver and kidneys is not unusual.

On the fourth day after admission the patient's condition was much improved. The pain in his thighs was almost completely gone and his general condition was good. His CRP had fallen to 45, thrombocytes had risen to 89 and estimated GFR was 49. Liver enzymes were still rising. The patient was discharged to his home with further doxycycline treatment. At a blood test follow-up a few days later his CRP was 3 and his liver enzymes and kidney function tests had almost normalised. At an outpatients examination a week after discharge, the patient was in good shape and had no symptoms. The diagnosis was confirmed by positive leptospirosis serology. The antibiotics course was completed seven days after discharge. In response to telephone follow-up, the patient stated that he had reverted to his normal state of fitness in the course of a few weeks, and had started rowing and other exercise again.

Discussion

Leptospirosis is the designation for a group of zoonoses caused by the bacteria *Leptospira interrogans* which is related to spirochetes (4). The name reflects the bacterium's appearance: Leptos means narrow or fine, while speira is the Greek word for spiral. The incubation period of leptospirosis is 2–20 days, and in most cases the infection has a subclinical or mild, influenza-like course. Fever, headache and myalgia are common symptoms, while abdominal pain, conjunctivitis and exanthema occur less frequently. In septic courses, affection of the liver and kidney, meningitis or encephalitis, myocarditis and pulmonary symptoms such as coughing and dyspnoea are also seen. The septic phase may last for up to a week. Without treatment, the fever often abates after a week, but some patients have relapses of fever for a further 1–2 weeks. Some of the organic symptoms of the disease are probably due to immunological responses to the infection. In serious courses, thrombocytopenia, leukocytosis with neutrophilia, icterus and mi-

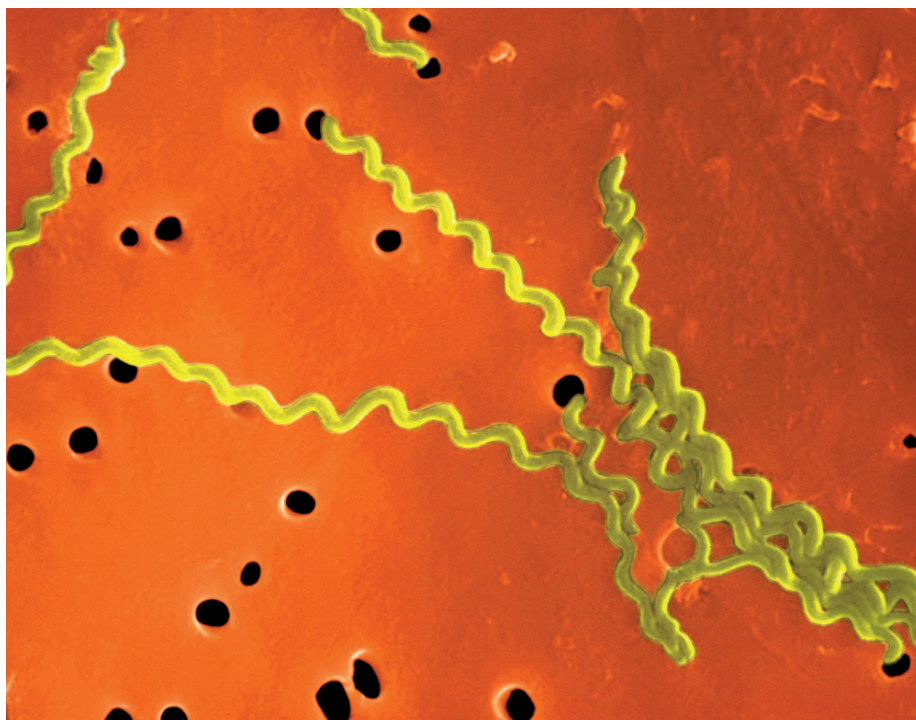


Figure 1 *Leptospira interrogans*. Electron microscopy. Photo T. Carvalho/Visuals Unlimited/Corbis/Scanpix

croscopic haematuria are common (3). Hypokalaemia and hyponatraemia are often seen and are probably due to the ability of the bacteria to inhibit active Na-K-Cl co-transport in the ascending limb of Henle's loop in the kidneys (5, 6). Electrolyte imbalances may be exacerbated by diarrhoea and renal failure. Mortality for serious leptospirosis is about 10%, even with appropriate antibiotic treatment (3, 7).

Although the combination of travel history, symptoms and clinical findings may give rise to suspicion of leptospirosis, a number of other infectious diseases are also possible differential diagnoses. Milder forms of leptospirosis can be confused with influenza or similar viral infections. In our case history, nephropathia epidemica was a possible differential diagnosis, while human granulocytary ehrlichiosis and rickettsioses were far less probable. The clinical findings in cases of dengue fever are also sometimes similar to leptospirosis, but a short incubation period and the travel destination excluded this disease in our patient. Because of elevated liver values, viral hepatitis was another possibility. With hepatitis A in particular there is fever and muscular aching in the preicteric phase.

In this case, however, the patient's travel account was typical and the disease picture classical for severe leptospirosis? Weil's disease? and the diagnosis was confirmed by positive serology. A serological test is the most important means of diagnosing leptospirosis. In Norway, leptospirosis serology is performed at the Norwegian Institute of Public Health. The test used there detects both IgM and IgG. The sensitivity and speci-

ficity are over 95%, and the positive predictive value for identification of acute leptospirosis is 90% (8). Leptospirosis can also be diagnosed by detecting the bacteria in cultures of blood, urine, spinal fluid or other bodily fluids on a special medium. In the acute septic phase in particular *Leptospira* can be detected in blood. As culturing usually requires a special medium, the referral to the laboratory must indicate that *Leptospira* is suspected. The bacteria grow slowly, and it may be several weeks before they can be detected in a culture (3). In our patient, *Leptospira* was not found in cultures of urine or blood taken at the time of admission. This may be because culturing on a special medium was not requested, or because the microbe was no longer present in the patient's blood or urine.

When it comes to treatment, there is not an adequate scientific knowledge base for setting clear guidelines for the choice of antibiotic. Penicillin, ampicillin, doxycycline and ceftriaxone all appear to be effective as long as treatment starts early in the course (9). If leptospirosis had been suspected at the time of admission of our patient, a narrow-spectrum antibiotic with less potential for developing resistance, such as penicillin, would probably have been the first choice. But treatment with ceftriaxone also caused a rapid improvement in his condition.

In Norway, leptospirosis is primarily an imported disease affecting persons who have been in contact with fresh water contaminated with infected animal urine. The bacteria can survive for several months in water and moist soil. They can penetrate skin or be transmitted if contaminated water

is swallowed or comes into contact with wounds, for example during bathing, rowing and other water sports. Rats are probably the most frequent source of infection, but dogs, pigs, cattle, horses and hedgehogs may also be reservoirs for some serotypes (4). Men appear to be more susceptible to infection than women (10). The bacteria occur worldwide, but most frequently in tropical areas (3). However, leptospirosis has been detected in dogs in Norway in recent years, a sign that the bacteria also occur in this country (4). Since detection requires a special medium and tests are seldom performed unless there is suspicion of an imported disease, it is possible that there are also undiagnosed cases of the disease in Norway. If antibiotics that are often administered in the case of unclear infection conditions are effective, this may also lead to the prevalence being underestimated.

So the patient's relative (and the department's infectious diseases doctors) were right. Our patient was probably infected while rowing on fresh water in southern France 1–2 weeks before his admission, and the wound on his right elbow may have been the port of entry for the microbe. When the disease is less acute, it is more difficult to make a diagnosis. In cases of serious influenza-like symptoms in persons who have been exposed to fresh water in endemic areas in recent days or weeks, tests should be ta-

ken with leptospirosis in mind, and treatment started if there is suspicion of leptospirosis.

The patient has consented to the publication of the article.

Marius Myrstad (born 1978)

Doctor in specialist training in internal medicine and geriatrics at the Medical Department, Diakonhjemmet Hospital.

Conflicts of interest: None declared

Kiarash Tazmini (born 1976)

Doctor in specialist training in the Medical Department, Diakonhjemmet Hospital.

Conflicts of interest: None declared

Knut H. Spæren (born 1969)

Specialist in internal medicine and infection medicine, Lead Auditor's diploma. Senior Consultant in the Medical Department and Senior Consultant, Infections at Diakonhjemmet Hospital. He is a member of the National Committee for Food-Borne Diseases.

Conflicts of interest: None declared

Aira Bucher (born 1949)

Specialist in infection diseases and Head of Department and Senior Consultant at the Medical Department, Diakonhjemmet Hospital, Oslo.

Conflicts of interest: None declared

Litteratur

1. Norrländska infektionssjukdomar. I: Iwarson S, Norrby R, red. Infektionsmedicin. Epidemiologi, klinik, terapi. Sävedalen: Säve förlag, 2007: 370–81.
2. Kristiansen BE, Jenkins A, Tveten Y et al. Human granulocytær ehrlichiose i Norge. Tidsskr Nor Lægeforen 2001; 121: 805–6.
3. Icke inhemske bakterielle infeksjoner. I: Iwarson S, Norrby R, red. Infektionsmedicin. Epidemiologi, klinik, terapi. Sävedalen: Säve förlag, 2007: 382–93.
4. Leptospirose. I: Smittevernhandboka. 3. utg. Oslo: Nasjonalt folkehelseinstitutt, 2005: 98.
5. Wu MS, Yang CW, Pan MJ et al. Reduced renal Na⁺-K⁺-Cl⁻ co-transporter activity and inhibited NKCC2 mRNA expression by *Leptospira shermani*: from bed-side to bench. Nephrol Dial Transplant 2004; 19: 2472–9.
6. Krishnan A, Karnad DR, Medhekar TP. Paralysis due to renal potassium wasting: an unusual presentation of leptospirosis. Nephrol Dial Transplant 2003; 18: 2454–5.
7. Senior K. Leptospirosis and Weil's syndrome: cause for concern? Lancet Infect Dis 2010; 10: 823–4.
8. Serion Elisa classic. *Leptospira* IgG/IgM. www.virion-serion.com/71.0.html?&L=1 [27.3.2011].
9. Bharti AR, Nally JE, Ricaldi JN et al; Peru-United States Leptospirosis Consortium. Leptospirosis: a zoonotic disease of global importance. Lancet Infect Dis 2003; 3: 757–71.
10. Scott G, Coleman TJ. Leptospirosis. I: Gordon CC, Alimuddin Z, red. Manson's Tropical Diseases. 21. utg. London: Saunders, 2003: 1165–70.

Received 23 November 2010, first revision submitted 5 April 2011, approved 10 November 2011.

Medical editor Are Breen.

Comment

Tourism, climate change and diagnostics

Travel and climate are important factors in the spread of a number of infectious diseases. Global warming and increasing precipitation provide better conditions for the spread of many diseases that are transmitted by means of mosquitoes, other insects and animals. As a result, travel within Europe can also result in diseases that do not normally occur to us unless the patient has been in warmer, more remote places. A number of these diseases are therefore underdiagnosed, partly because of lack of awareness and partly because the diagnostics require special tests (1, 2).

Since 2007, cholera infection has been reported in France, spreading of Chikungunya fever in Italy, malaria in Italy and Greece and dengue fever in southern France. West Nile Fever was established in Romania as early as in 1960, and from there it has spread several times to other European countries with birds and mosquitoes as the vector chain (2). Outbreaks of leptospirosis have been associated with floods, and have been reported from a

number of European countries as well as from developing countries (1, 3–6).

A number of these diseases require specific, targeted diagnostic measures before the diagnosis can be confirmed. Patients are often hospitalised with suspected septicaemia, and blood cultures are used to try to confirm the diagnosis. Perhaps the most important reason for being unable to confirm a diagnosis is that the patient has had antibiotics before hospitalisation. But the bacteria in a number of infections, such as leptospirosis, brucellosis and tularaemia, will grow poorly in an ordinary blood culture under any circumstances. Some require a longer incubation time than the usual five days; some require special media. Other syndromes can be detected most easily by means of specific serological tests and polymerase chain reaction tests (PCR) (4).

The diagnostics therefore depend on sound knowledge and an awareness of the possibilities that exist. If they obtain adequate information, microbiology depart-

ments can set up specialised analyses themselves. In other cases, specialised analyses must be ordered. It is therefore important to have a good patient history – where have you been, when, and what did you do?

The diagnostics of «imported fevers» are important because several of the diagnoses in question require specific treatment. This applies, for instance, to typhoid fever, rickettsioses and malaria, where ordinary antibiotics treatment often does not work.

Leptospirosis is the most common bacterial zoonosis. It is produced by a number of pathogenic species that may have various rodents and some other animals as asymptomatic carriers. Rain and flooding are important factors in the spread of *Leptospira*. Water becomes contaminated by chronic carriers among rats and other rodents that excrete *Leptospira* in their urine. Under favourable conditions, the bacteria can survive in water for many months.

There has been a substantial increase in incidence among tourists, particularly in con-