

A man with fever and joint pain

Joint pain can have many causes. Immunological and infectious diseases, as well as trauma, must be considered. A good case history can put us on the right track early on.

A Norwegian man in his sixties was admitted to the Department of Medicine owing to severe pain in the right ankle. The pain was accompanied by intermittent fever above 39 °C. Apart from hospitalisation for malaria in 2011, he had otherwise been mostly in good health. The patient took Albyl-E 75 mg 1 × 1 as primary prophylaxis against heart disease. He had returned to Norway five days earlier from a stay abroad. During the journey and for two weeks prior to admission, he had noticed transient nasal congestion and a sore throat. Upon admission he had increasing pain in the right ankle. He had sprained the ankle a month earlier, but there was no major trauma in his case history. He also reported general pain in the shoulders, back and left hip. Upon arrival at the hospital, the patient had a high fever with temperature 39 °C, normal blood pressure (119/65), and a steady pulse of 86. Auscultation of the heart and lungs was normal. He had diffuse rubor on both the medial and the lateral side of the right ankle, as well as warmth and a petechial rash over the ankle joint (Fig. 1).

Blood tests on admission revealed CRP 248 (< 5 mg/l), leukocytes 21.5 (3.5–11.0 × 10⁹/l) with neutrophil granulocytes 19.4 (1.7–8.2 × 10⁹/l), thrombocytes 186 (145–348 × 10⁹/l), INR 1.3 (< 1.1), sedimentation rate 15 (1–20), creatinine 92 (60–105), bilirubin 26 (< 19), LD 244 (105–205) and CK 79 (40–280).

The orthopaedic surgeon was consulted in the emergency ward. By this stage the blood test results were also available. Diagnostic puncture of the ankle joint was indicated, but not X-ray examination of the ankle. A total of 2–3 ml of opaque synovial fluid was drained from the right ankle around midnight on the day of admission, but drainage of all of the synovial fluid was not possible due to pain. The synovial fluid was sent for cultivation and microscopy, but not for cell counting.

At this point we opted for empirical treatment with intravenous cloxacillin and gentamicin to cover septic arthritis. We initially considered reactive arthritis to be the most likely diagnosis, but a high CRP level and neutrophilic leukocytosis, in addition to high fever, led us to provide antibiotic coverage in addition.

The following morning, the patient was still febrile and his CRP level had risen to 317.

The preliminary results from the Department of Microbiology arrived at about the same time: synovial fluid microscopy showed gram negative cocci in pairs and abundant leukocytes. The microbes could be seen intracellularly (Fig. 2).

These findings meant that the most common causes of septic arthritis – *Staphylococcus aureus* and *Streptococcus* species – were less likely in this case. On the basis of the microscopy results we now suspected gonococcal infection and changed the antibiotic coverage to intravenous ceftriaxone 2 g 1 × 1.

On the first day of hospitalisation, the patient was thus referred to the outpatient clinic for sexually transmitted diseases. He was now subfebrile and had less pain in the ankle.

Samples were taken from the urethra and tonsillar region to test for gonococci and chlamydia, in addition to serology to test for syphilis, HIV and hepatitis viruses. It eventually came to light from the case history that the patient had had unprotected sex in countries outside Europe on a couple of occasions in the past year.

Two days after admission, the ankle was swollen and red but with a good range of movement. We punctured the ankle again and aspirated 1 ml of clear fluid. Two days later, we repeated the puncture and aspirated 3 ml of purulent fluid. A total of 5 ml of straw-coloured fluid was also aspirated from the patient's right knee because of increased swelling. The final microbiology results now revealed growth of *Neisseria gonorrhoeae* from the synovial fluid aspirated from the right ankle upon admission, on both blood agar and chocolate agar. The microbe was catalase-positive and showed agglutination in serogroup W1. The identity of the bacteria was confirmed using both the Vitek II system and MaldiToF (bioMérieux) mass spectrometry technology. The microbe was resistant to penicillin G, ampicillin and ciprofloxacin, but sensitive to ceftriaxone, azithromycin and spectinomycin.

The need for arthroscopic irrigation was evaluated on an ongoing basis. The procedure was not carried out, however, owing to biochemical and local improvement.

Olav Lutro

olav.lutro@helse-bergen.no
Department of Medicine
Haukeland University Hospital

Kristine Lillebø

Department of Microbiology
Haukeland University Hospital

Johannes Cornelis Schrama

Department of Orthopaedic Surgery
Haukeland University Hospital

Håvard Dale

Department of Orthopaedic Surgery
Haukeland University Hospital

Haakon Sjørusen

Department of Medicine
Haukeland University Hospital

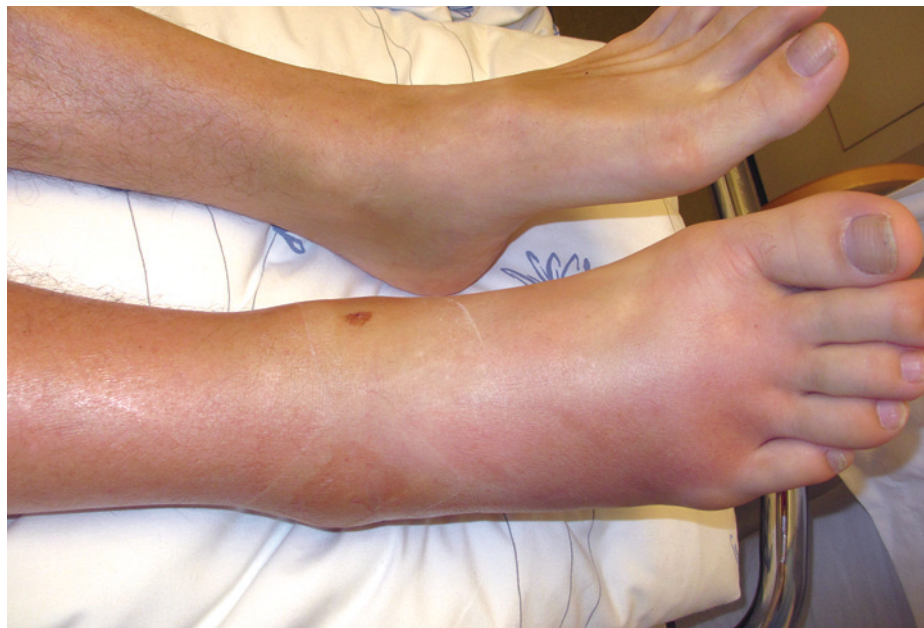

Figure 1 Right ankle upon admission. Photograph: Astrid Rykkje Heien

After ten days of antibiotic treatment, the patient was still experiencing fever and pain, and CRP remained elevated at 145. We therefore chose to administer prednisolone, initially 40 mg 1 × 1 for four days, followed by gradual tapering over three weeks. Two days after initiation of prednisolone, the patient became afebrile and his CRP level decreased rapidly. Seven days later, the patient was discharged with oral azithromycin, and prednisolone in decreasing doses. His CRP level

was at that point 6. He was told that he could use the ankle to pain threshold and received instructions from a physiotherapist regarding exercises.

Secretions from the urethra and throat tested negative for gonococci, and blood cultures were negative. A urine sample tested negative for *Chlamydia trachomatis* DNA, and serological tests for syphilis (*Treponema pallidum*-specific antibody) and HIV antigen/antibody were also negative. The patient was monitored weekly in the outpatient clinic. The swelling gradually improved, CRP remained normal and the patient reported less pain. Prednisolone and antibiotics were discontinued after 3 and 4.5 weeks of treatment respectively (18 days intravenous ceftriaxone, azithromycin × 3/week for 2.5 weeks).

After discontinuation of treatment, the patient experienced increasing oedema and pain in the right knee, accompanied by an increase in his CRP level to 43. He was readmitted, and 15 ml of yellowish fluid was aspirated from the knee joint. This was analysed with cell counting (leukocytes $5.7 \times 10^9/l$), but microscopy and cultures were negative. The rheumatologist injected 2 ml of Lederspan (a corticosteroid preparation) as we now considered the patient to have post-infectious reactive arthritis. At a check-up one week later, his CRP level had fallen to 1. The CRP level subsequently increased slightly to 17, and he was treated with diclofenac 50 mg 1 × 3 for one week. At the final check-up, his CRP level was < 1, SR level was 2, and he had mild oedema in the knee, but no pain.

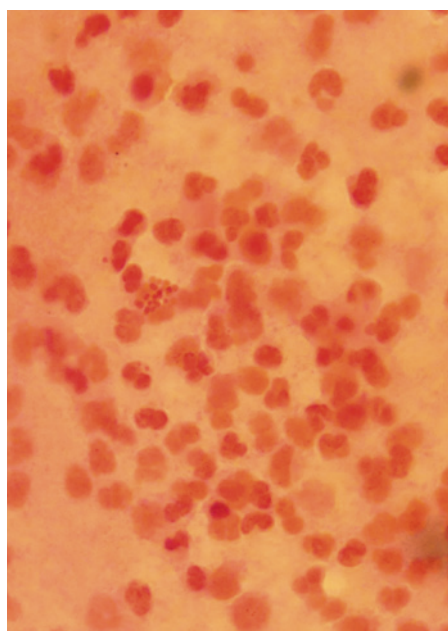


Figure 2 Microscopy results. Gram stain showing gram-negative diplococci from puncture of the right ankle

Discussion

In cases of fever and monoarthritis, initial diagnoses to consider are septic arthritis, reactive arthritis or crystal arthritis. When polyarthralgia is present in addition, systemic diseases such as adult-onset Still's disease or viral arthritis may also be relevant. The number of differential diagnoses is increased if the symptoms arose in connection with travel in the tropics. It is essential to puncture the joint for synovial fluid analysis and to perform blood cultures.

Gonococcal arthritis is a recognised but relatively rare cause of septic arthritis. In Norway, there are 1–2 confirmed cases of gonococci in synovial fluid each year (Øyvind Nilsen, MSIS, Norwegian Institute of Public Health, personal communication). Gonococcal infection usually causes urethritis and cervicitis, but from the literature it is known that 0.5–3% of those with mucosal gonococcal infection will develop disseminated gonococcal infection (1–3). The majority of disseminated gonococcal infections, 42–85%, present with arthritis (2). In Norway, there have been 12 confirmed cases of gonococci in synovial fluid over the past decade, out of a total of 3 682 cases of gonococcal infection, corresponding to 0.3% (Øyvind Nilsen, personal communication).

Disseminated gonococcal infection typically entails purulent arthritis or a syndrome with tenosynovitis, dermatitis and polyarthralgia, or a combination thereof (4, 5).

This patient had evident septic arthritis, with purulent synovial fluid and bacterial growth. This was accompanied by clinical tenosynovitis, dermatitis and polyarthralgia. The main symptoms were severe pain in the right ankle, accompanied by high fever and general body aches. In addition, examination revealed erythema on the right calf, petechial rash on the right foot and oedema in the right knee. He also had general pains in the shoulders, back and left hip.

Invasive gonococcal infection is associated with complement deficiency and systemic lupus erythematosus (SLE), but our patient showed no evidence of these. He tested negative for antinuclear antibodies (ANA), and complement testing was normal.

Diagnostics, resistance and treatment duration

Direct microscopy of synovial fluid has a high false negative rate with respect to septic arthritis, with reported sensitivity ranging from below 50% to 78% (6, 7).

The method is nevertheless still used in severe infections where findings from microscopy could have therapeutic implications. Our patient was quickly switched to the appropriate antibiotics on the basis of findings from microscopy. Several micro-

Gonorrhoea reported to the National Surveillance System for Communicable Diseases, by detection method

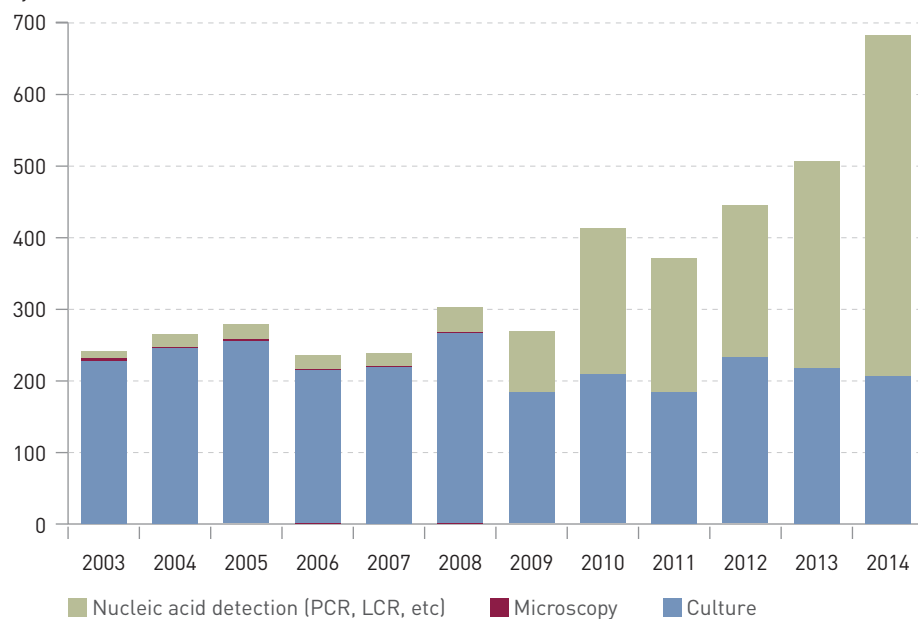


Figure 3 Overview of the number of reported cases of gonorrhoea, incidence shown stratified by detection method (10). The illustration is based on a figure from the Norwegian Institute of Public Health and is reproduced courtesy of Øivind Nilsen

biological laboratories in Norway can now also rapidly detect gonococci via nucleic acid amplification tests (PCR).

The isolate was resistant to ampicillin and ciprofloxacin. Of the antibiotics to which the isolate was sensitive, only ceftriaxone and azithromycin were licensed in Norway, while spectinomycin had to be ordered with a delivery time of approximately three weeks.

The literature indicates that 7–10 days of treatment are usually sufficient for gonococcal arthritis (8). We chose to continue treatment for significantly longer because of persistent pain, fevers and high levels of inflammatory markers. We therefore opted for intravenous ceftriaxone initially, and provided coverage with oral azithromycin for the duration of the adjuvant steroid therapy.

Adjuvant steroid therapy was used because the persistent fevers were regarded as immunological in origin, and the oedema in the right knee was considered to be reactive arthritis (8).

Surgical treatment:

Drainage versus irrigation

In general, arthroscopic irrigation is recommended in the case of septic arthritis. For gonococcal arthritis, either irrigation or repeated punctures are recommended. We opted for repeated punctures (8). There was only a small amount of synovial fluid, so there appeared to be little risk of damage to the joint.

There are thought to be at least 78 million new cases of gonorrhoea worldwide each year (9). In Norway, detection of *Neisseria*

gonorrhoeae must be reported to the National Surveillance System for Communicable Diseases. The Norwegian Institute of Public Health has reported a steadily increasing incidence in recent years (10) (Fig. 3).

A worrying increase in ciprofloxacin-resistant isolates has long been observed both in Norway and internationally, and led to ciprofloxacin being abandoned as empirical treatment in Norwegian guidelines in 2013 (11, 12). Cephalosporin resistance is also increasing worldwide, and gonorrhoea is becoming increasingly difficult to treat (13).

Our patient had an atypical clinical presentation. The incidence of gonorrhoea is increasing and it is important that health care personnel and persons in high risk groups are alert to the disease, including its less common symptoms.

The patient has consented to the publication of the article.

We wish to thank Øivind Nilsen, senior advisor at the Department of Infectious Disease Epidemiology, Norwegian Institute of Public Health, for assistance with the manuscript.

Olav Lutro (born 1973)

specialist in infectious diseases and senior consultant, with a particular interest in orthopaedic infections. The author has completed the ICMJE form and reports no conflicts of interest.

Kristine Lillebø (born 1981)

specialty registrar in medical microbiology, currently based in the Division of Infectious Diseases and Tropical Medicine, Department of Medicine, Haukeland University Hospital. The author has completed the ICMJE form and reports no conflicts of interest.

Johannes Cornelis Schrama (born 1960)

specialist in orthopaedic surgery and senior consultant. The author has completed the ICMJE form and reports no conflicts of interest.

Håvard Dale (born 1966)

specialist in orthopaedic surgery and senior consultant. The author has completed the ICMJE form and reports no conflicts of interest.

Haakon Sjørnsen (born 1947)

specialist in internal medicine and infectious diseases, and senior consultant. He is also a professor at Clinical Institute 2, Faculty of Medicine and Dentistry, University of Bergen. The author has completed the ICMJE form and reports no conflicts of interest.

References

- Shirliff ME, Mader JT. Acute septic arthritis. *Clin Microbiol Rev* 2002; 15: 527–44.
- O'Brien JP, Goldenberg DL, Rice PA. Disseminated gonococcal infection: a prospective analysis of 49 patients and a review of pathophysiology and immune mechanisms. *Medicine (Baltimore)* 1983; 62: 395–406.
- Holmes KK, Counts GW, Beaty HN. Disseminated gonococcal infection. *Ann Intern Med* 1971; 74: 979–93.
- Bennett JE, Dolin R, Blaser MJ. Mandell, Douglas, and Bennett's principles and practice of infectious diseases. 8. utgave. Elsevier Saunders 2014: 1448–91.
- Barth WF, Segal K. Reactive arthritis (Reiter's syndrome). *Am Fam Physician* 1999; 60: 499–503, 507.
- Goldenberg DL. Septic arthritis. *Lancet* 1998; 351: 197–202.
- Stirling P, Faroug R, Amanat S et al. False-negative rate of gram-stain microscopy for diagnosis of septic arthritis: suggestions for improvement. *Int J Microbiol* 2014; 2014: 830857.
- Bardin T. Gonococcal arthritis. *Best Pract Res Clin Rheumatol* 2003; 17: 201–8.
- Newman L, Rowley J, Vander Hoorn S et al. Global estimates of the prevalence and incidence of four curable sexually transmitted infections in 2012 based on systematic review and global reporting. *PLoS One* 2015; 10: e0143304.
- Folkehelseinstituttet. Gonoré og syfilis i Norge 2014. <https://fhi.no/globalassets/migrering/dokumenter/pdf/gonore-syfilis-2014.pdf> [25.10.2016].
- Moi H. Ny behandlingsanbefaling ved gonoré. *Tidsskr Nor Legeforen* 2013; 133: 1169.
- Hjelmevoll SO, Golparian D, Dedi L et al. Phenotypic and genotypic properties of *Neisseria gonorrhoeae* isolates in Norway in 2009: antimicrobial resistance warrants an immediate change in national management guidelines. *Eur J Clin Microbiol Infect Dis* 2012; 31: 1181–6.
- Wright DJ, Azadian B. Cephalosporin resistance in gonorrhoea. *Lancet Infect Dis* 2013; 13: 728–30.

Received 22 March 2016, first revision submitted 16 August 2016, accepted 25 October 2016. Editor: Liv-Ellen Vangsnæs.